

# MIA Life

MODE IMPLANT ACADEMY

2019

#3  
SPECIAL PUBLICATION

IMPLANTOLOGY  
MAGAZINE

**INTERNATIONAL  
LECTURES & EVENTS**

**CLINICAL CASE  
PRESENTATIONS**

**SCIENTIFIC STUDIES**

**ANALYSIS REPORTS &  
CERTIFICATES**

JUST in 3 YEARS  
39 INTERNATIONAL  
TOTAL

**120**  
EVENTS

**SCIENCE  
JOINS TOGETHER  
WITH QUALITY**

MODE MEDIKAL®

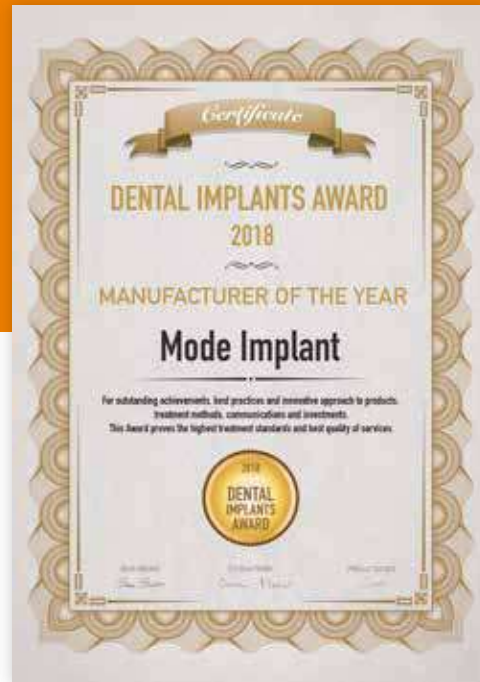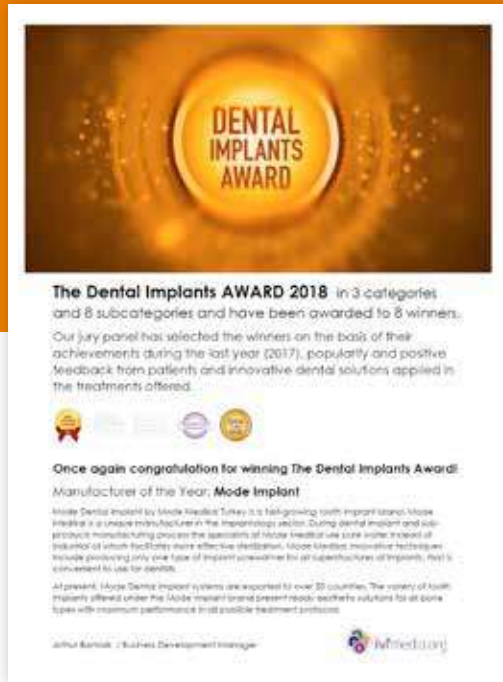**MODE**  
IMPLANT

**MIA**  
MODE IMPLANT ACADEMY




# “THE MANUFACTURER OF THE YEAR” AWARD

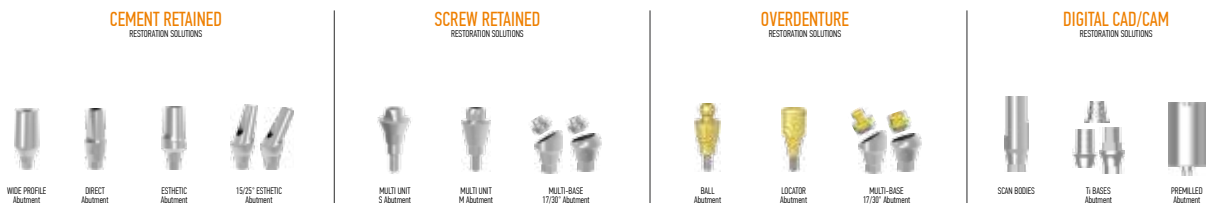P R O U D L Y



## PROUDLY AWARDED “THE MANUFACTURER OF THE YEAR” FROM USA ON OUR 11<sup>th</sup> ANNIVERSARY



CREATE YOUR NATURAL ESTHETICS FROM INDICATIONS TO RESTORATIONS WITH WIDE RANGE SOLUTIONS...





**PROF. DR. HASAN MERIC**  
PERIODONTOLOGY, PhD  
MIA DIRECTOR  
  
ISTANBUL AYDIN  
UNIVERSITY

**Dear colleagues,**

We are proud of completing our 120<sup>th</sup> scientific activity in just three years with an academic and scientific power.

Traces of advancing technology beyond dreams have brought many innovations to the field of dentistry and this has led to intensive research and study. While preparing our scientific studies, we provided all the material we need with our main sponsor, Mode Implant.

Mode Implant is present in more than 40 countries and in 2018 was awarded as "Manufacturer of the Year" and has 2 Gold Medals from Genève and Germany for the success of Mode RAPID implants in primary stabilization with scientific studies that were academically documented.

MIA team has accomplished many successful scientific studies in the sector, aims to be a source of reference in the national and international arena with the awards, experience and self-confidence.

With my love and respect



**OGUZ AKYUZ**  
MECH. ENGINEER  
FOUNDER, CEO  
IMPLANTER PRESIDENT

**11th Year in the Dentistry Market**

Mode Medikal, which celebrate its eleventh year in 2019, continues its journey with the aim of becoming a Worldwide Brand.

I would like to take this occasion to thank my family, Mode Medikal staff and you, our dentists who use Mode Implant, believe and support us since the day we were established. Innovative Mode Medikal adds new trend products for medical sector, in synergy with quality and high technology...

# INDEX

## ABOUT MIA & COLLABORATIONS

06-17



## LECTURES AND EVENTS

18-39

## SCIENTIFIC STUDIES

40-55



2019

#3

SPECIAL PUBLICATION

**MIA** Life  
MODE IMPLANT ACADEMY

IMPLANTOLOGY  
MAGAZINE

**Mode Implant Academy  
Grand Holder**  
Oguz Akyuz

**Mode Implant Academy  
Director**  
Prof. Dr. Hasan Meric

**Editors**  
Suraie Germanova  
Saniye Ozgur  
Kubra Kayaokay

**Editorial Board**  
Dr. Ugur Meric  
Dr. Ugur Mercan  
Dr. Ferhat Mısır  
Dr. M. Sabri Sencan  
Dr. Guvenc Uz  
Dr. Volkan Arıcı  
Dr. A. Selhan Kaya  
Dt. Ahmet Kigili  
Dr. Defne Burduroğlu  
Dr. Yuliya Slinko  
Dr. Fisnik Kasabi  
Dr. Kerem Turgut Atasoy  
MSc. Dt. Gokhan Tunaligil  
Msc.Dt. Sinan Yuzbasioglu

**Address**  
Abdi İpekci Cad. No:58 Bayrampasa  
34030 Istanbul / Turkiye

**Social Media**  
f/modeimplant  
i/modeimplant

**Design**  
Gökhan Yıldırım

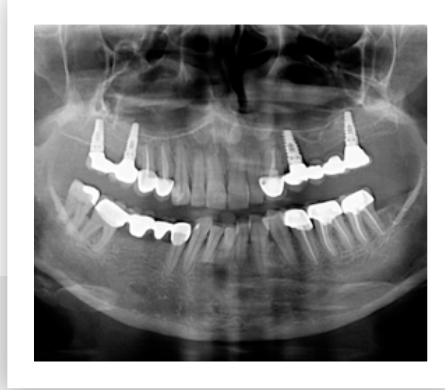**Print**  
Cagdas Form Matbaa  
Litros Yolu 2.Matbaacılar Sitesi  
2NC 24 Topkapı / İstanbul  
Tel: 0 (212) 544 95 55

**Publication**  
Yearly, periodic

**Web**  
www.miacademy.net

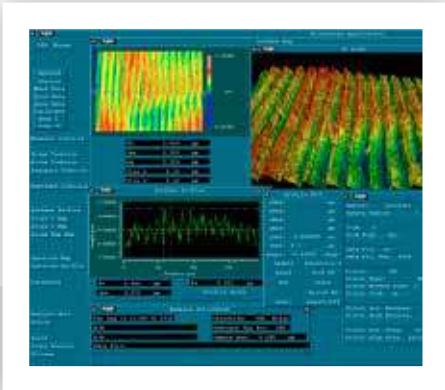
**CASE  
STUDIES**

56-69



**ANALYSIS  
REPORTS &  
CERTIFICATES**

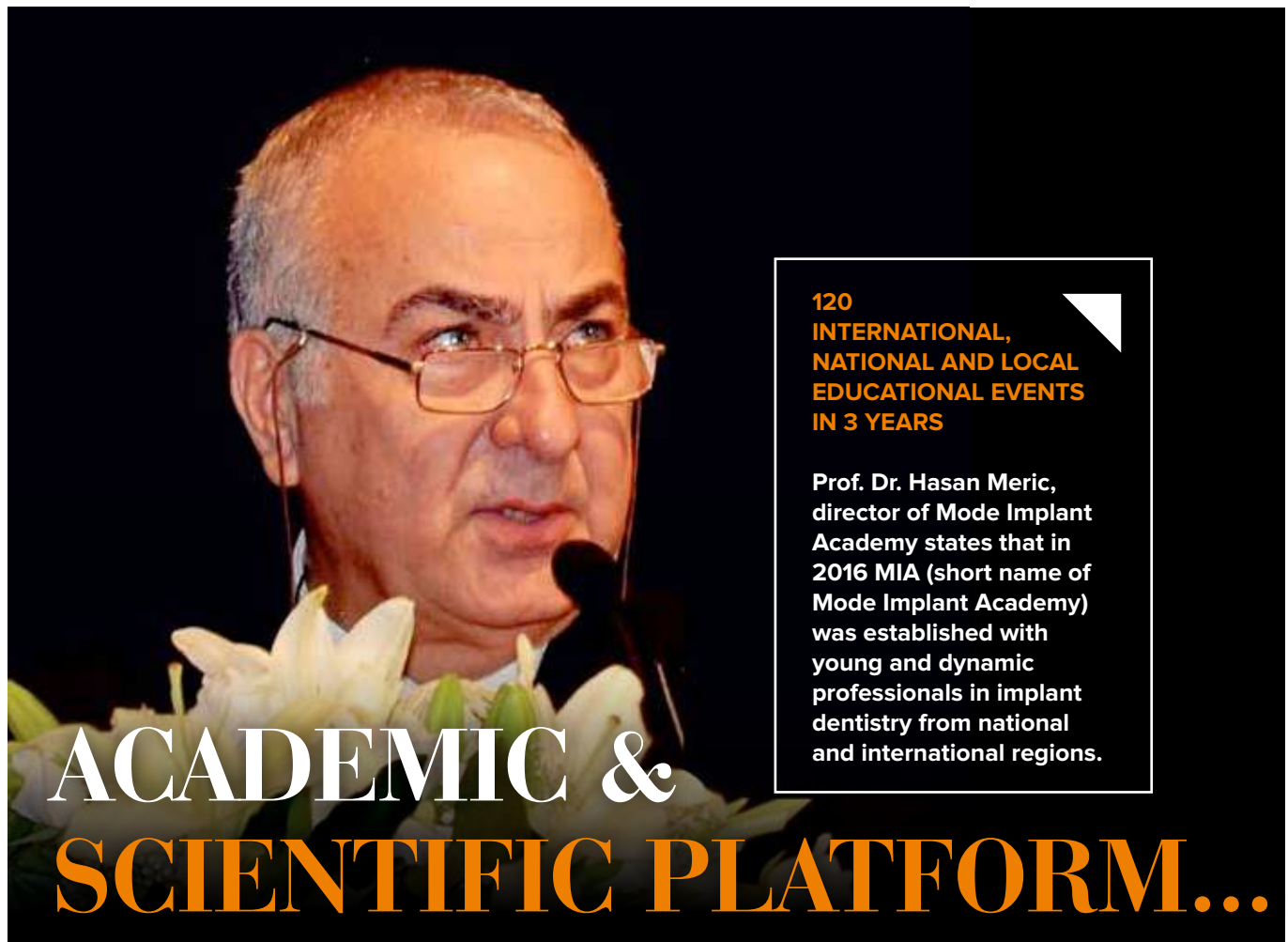70-73



**FUTURE  
EVENTS**

74-79





**120  
INTERNATIONAL,  
NATIONAL AND LOCAL  
EDUCATIONAL EVENTS  
IN 3 YEARS**

**Prof. Dr. Hasan Meric,  
director of Mode Implant  
Academy states that in  
2016 MIA (short name of  
Mode Implant Academy)  
was established with  
young and dynamic  
professionals in implant  
dentistry from national  
and international regions.**

# ACADEMIC & SCIENTIFIC PLATFORM...

MIA is an academic and scientific platform of the latest developments in implant dentistry as well as discussion of clinical questions and an exchange of experiences.

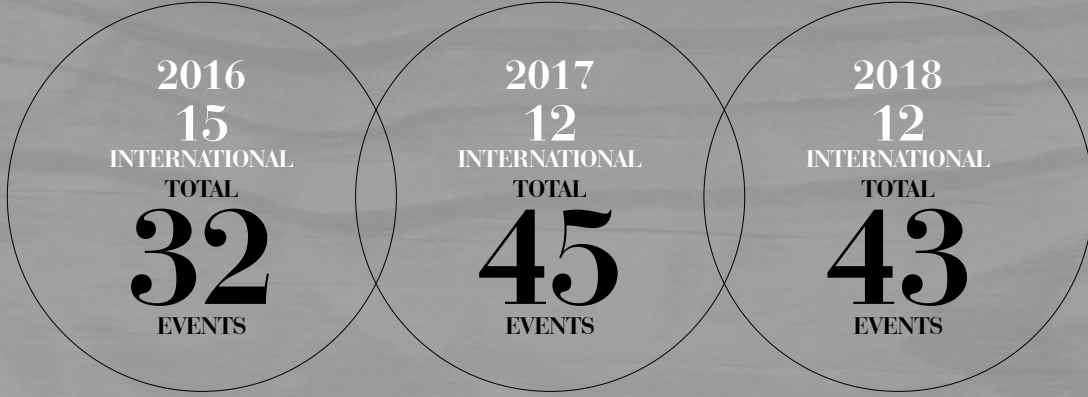This allows for interactive discussion for aspects of treatment planning, procedures, handling of complications and aspects of practice management and practice building.

Since MIA establishment well over 120 international, national and local educational events were realized. MIA aims to become a scientific reference source with comprehensive quality education and innovative research in the field of implantology.

## **MIA; MAIN SCIENTIFIC SUBJECTS**

- **Autogenous bone collection and application procedures in implant applications,**
- **Special techniques in alveolar bone augmentation,**
- **Implant planning and restoration preference according to patient,**
- **Pre-implant radiology, planning and evaluation,**
- **Immediate implant surgical protocols,**
- **Implantology in geriatric patients and atrophic crest**
- **Pre-operative planning for the Edante case**
- **Maxillary sinus anatomy,**
- **Conscious sedation and emergency treatment in surgery**
- **The Right Prosthetic options for implant treatments.**

SUCCESS OF  
**MIA**  
JUST IN  
3 YEARS



JUST in 3 YEARS  
39 INTERNATIONAL  
TOTAL  
**120**  
EVENTS



## MIA ACADEMIC STAFF

### ORAL, DENTAL AND MAXILLOFACIAL SURGERY



**DR. UĞUR MERİÇ**  
ORAL &  
MAXILLOFACIAL  
SURGERY DDS, PhD



**Assoc. Prof. DR. MUSTAFA RAMAZANOĞLU**  
ORAL &  
MAXILLOFACIAL  
SURGERY DDS, PhD



**ASST. PROF. DR. UĞUR MERCAN**  
ORAL &  
MAXILLOFACIAL  
SURGERY DDS, PhD



**ASSOC. PROF. DR. FERHAT MISIR**  
ORAL &  
MAXILLOFACIAL  
SURGERY DDS, PhD



**ASST. PROF. DR. M. SABRİ ŞENCEN**  
ORAL &  
MAXILLOFACIAL  
SURGERY DDS, PhD



**DR. A. SELHAN KAYA**  
ORAL &  
MAXILLOFACIAL  
SURGERY DDS, PhD



**DR. GÜVENÇ UZ**  
ORAL &  
MAXILLOFACIAL  
SURGERY DDS, PhD



**DR. VOLKAN ARICI**  
ORAL SURGEON  
DDS, PhD



**DR. ÜLKEM CURAL**  
ORAL &  
MAXILLOFACIAL  
SURGERY DDS, PhD

### PERIODONTOLOGY



**PROF. DR. HASAN GÜNEY YILMAZ**  
PERIODONTOLOGY,  
PhD



**DR. BAHADIR ŞATANA**  
PERIODONTOLOGY,  
PhD

### PROSTHETIC DENTISTRY



**PROF. DR. ONUR GEÇKİLİ**  
PROSTHETIC  
DENTISTRY



**DR. AHMET KİĞİLİ**  
PROSTHETIC  
DENTISTRY



**ASST. PROF. DR. DEFNE BURDUROĞLU**  
PROSTHETIC DENTISTRY

### ANESTHESIOLOGY



**ASST. PROF. DR. A. TOLGA ŞİTİLCİ**  
ANESTHESIOLOGY AND  
REANIMATION  
SPECIALIST

### MIA WORLDWIDE



**DR. FİSNİK KASAPI**  
ORAL MAXILLOFACIAL  
SURGERY DDS, PhD



**ASSOC. PROF. DR. YULIYA SLYNKO**  
ORAL MAXILLOFACIAL  
SURGERY DDS, PhD



**DR. HISHAM YOUSEF ABUELJEBAIN**  
ORAL MAXILLOFACIAL  
SURGERY DDS, PhD



**ASSOC. PROF. DR. HAKAN BILHAN**  
ORAL MAXILLOFACIAL  
SURGERY DDS, PhD



**PROF. DR. KIRO PAPAOKCA**  
PROSTHETIC  
DENTISTRY



**DR. SIBI XAVIER**  
MDS PERIO MASTER  
COORDINATOR



**FARIBA KHAYYATI**  
DIGITAL LAB  
TECHNICIAN



# UNIVERSITY COLLABORATIONS

The first academic support of our Academy comes from Biruni University... In 2016, MIA signed an agreement with Biruni University, Faculty of Dentistry in Istanbul with training, seminar, symposium courses and joint scientific planning.

We believe that university fellowship is important in our organizations where we believe that knowledge and experience sharing are beneficial. In addition to being scientific, we believe that the trainings will be more successful with cooperation and we carry out our studies in this line.

In addition to improving ourselves in the scientific and academic programs we have organized and gained a lot of friendships by the social sharing and we have become a big family. And in the light of the power and knowledge of every individual in our family, we take important steps and strengthen our organizations with collaborations on a scientific platform. Emphasizing the

importance of science and fellowship, we are happy to see you in our family.

**MIA SUCCESSFULLY COMPLETED THE EDUCATIONAL ORGANIZATIONS OF THE SERIES "NEW ERA IN IMPLANTOLOGY" COURSES, MIA SPRING SYMPOSIUM WITH THE FACULTY OF DENTISTRY AND OUR BASIC IMPLANTOLOGY TRAINING ORGANIZATIONS WITH THE INTERNATIONAL INTENSIVE PARTICIPATIONS.**



**PROF. DR. HASAN MERIC**  
MIA Director

As academicians of Biruni University, we support all aspects of the Mode Medikal Company and the MIA family, which are moving forward on their way to becoming a world brand with their high quality products and their activities in this field.



**PROF. DR. ADNAN YUKSEL**  
Rector of Biruni University

The fact that our scientific programs, where both biological and clinical principles in the implantology treatment of Istanbul Biruni University Faculty of Dentistry have been carried out in all aspects, have motivated us to work in this direction. We are proud of representing the first of this kind of scientific association in our country. We would like to express our gratitude to our esteemed Rector and all of our academics.



We have organized three activities in partnership with Biruni University; Spring Symposium, New Era series and Basic Implantology training organization of the university in the framework of the various methods of presentation by using a scientific program that conveyed knowledge and experience.

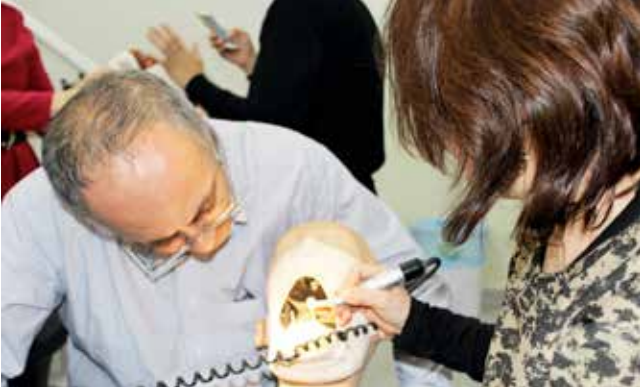**BIRUNI UNIVERSITY, FACULTY OF DENTISTRY, ISTANBUL**

# **BASIC IMPLANTOLOGY COURSES WITH UNIVERSITY APPROVED CERTIFICATE**

The most important goal of “Basic Implantology Training Program” is to increase the knowledge and skills of our just graduated dentists in implant treatment applications.

In the program organized in collaboration with Biruni University Faculty of Dentistry, trainee dentists are taught both the theoretical and practical applications of biological and basic clinical principles in implant treatment.





Fontom Surgery Hands-On



Protsthetic Hands-On



APPROVED UNIVERSITY CERTIFICATES WERE GIVEN IN THE END OF THE TRAINING AFTER LIVE SURGERIES, WHICH OCCURED IN CLINICS OF THE UNIVERSITY WITH MIA PROFESSIONALLS.

### BASIC IMPLANTOLOGY PROGRAM

#### Day 1

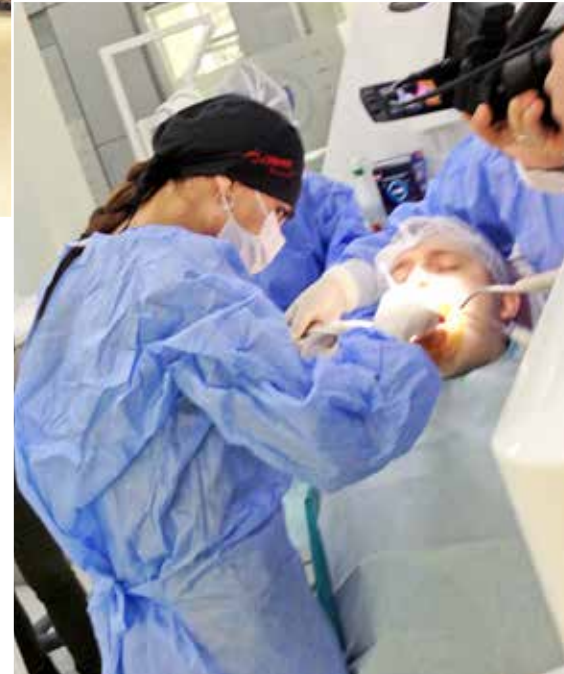Introduction to Implantology, Diagnosis and Treatment Plan, Surgical Procedures, Hands On

#### Day 2

Implant Supported Prosthesis Prosthetic Procedures Hands On

#### Day 3

Implant Live Surgery, Certificate Ceremony



Live Surgery

**KHARKIV NATIONAL MEDICAL UNIVERSITY, UKRAINE**



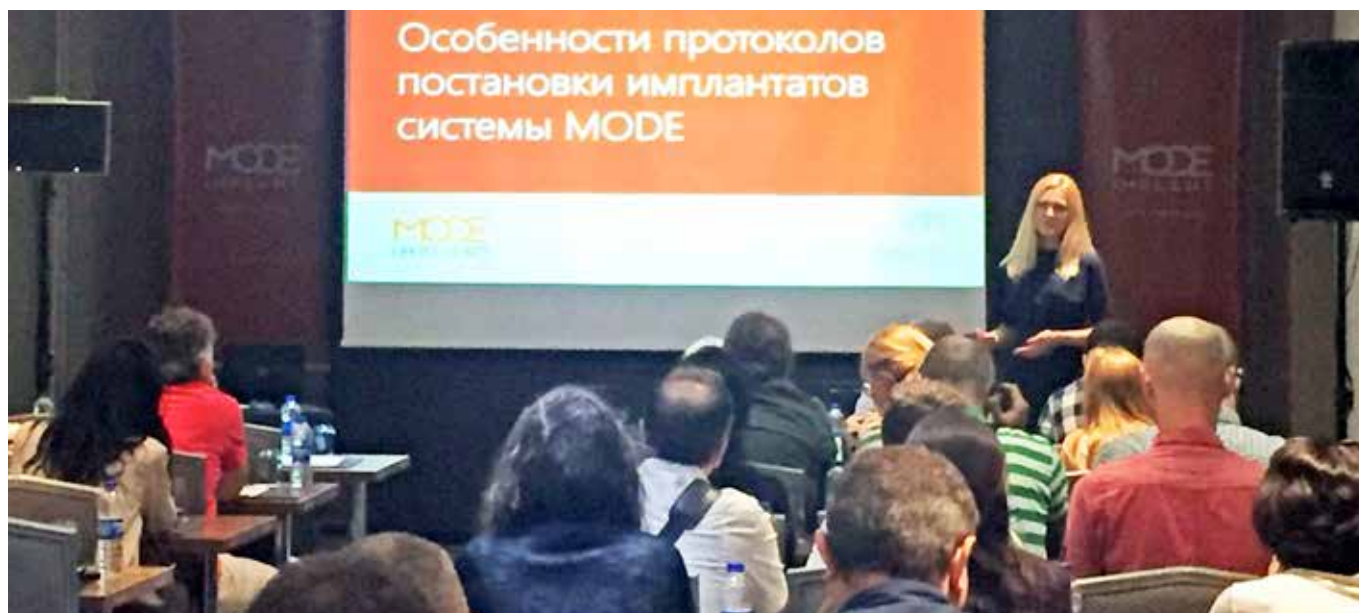# MIA UKRAINE

Since 2017, our academy is in collaboration with the Faculty of Dentistry of Kharkiv International Medical University, which is the one of the oldest state universities in Ukraine.

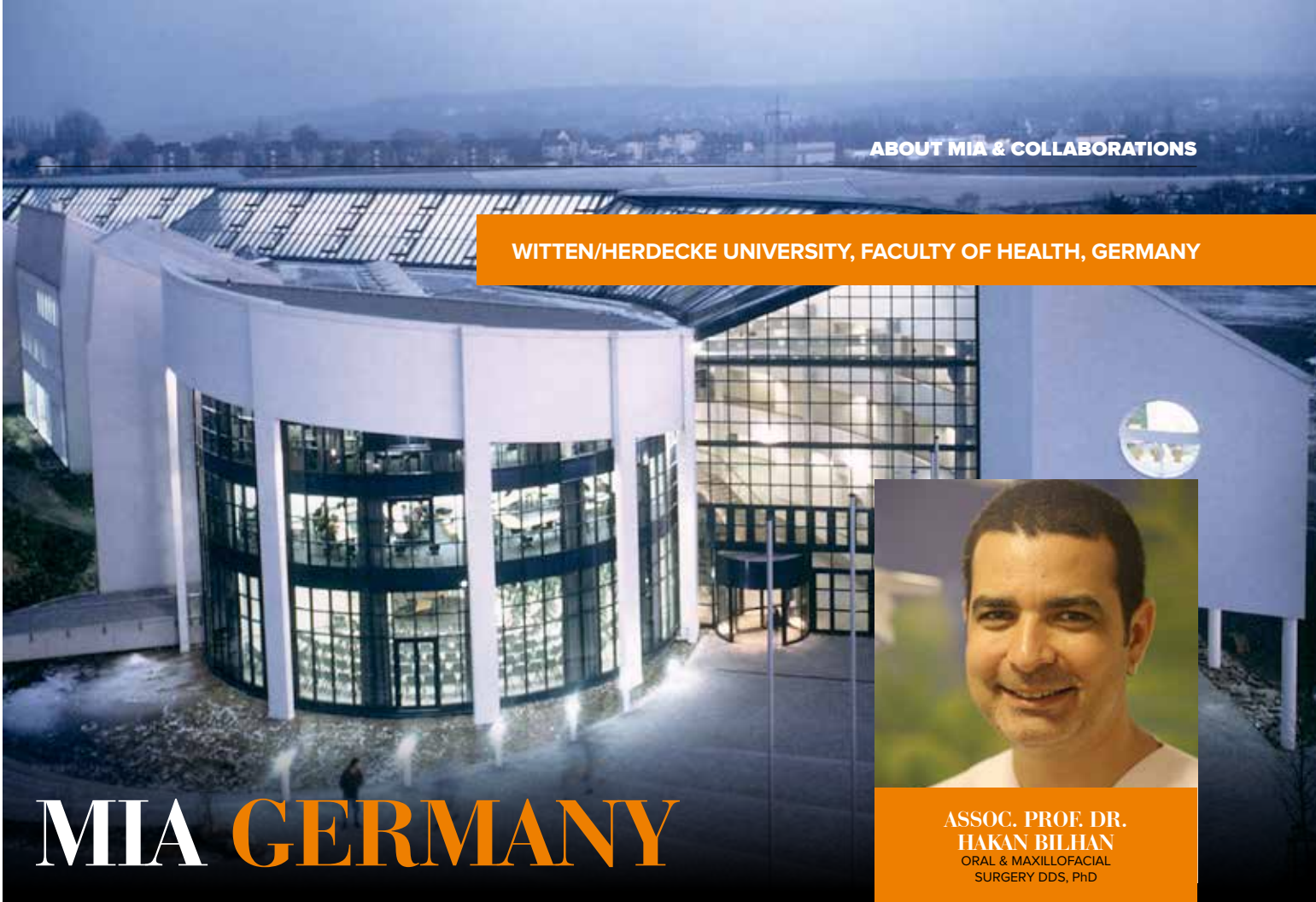Kharkov International Medical University, founded in 1805 in Ukraine. The Faculty of Dentistry has been in service since 1964. Oral and Maxillofacial Surgeon Dr. Yuliya Slinko: “About 7,000 students are studying in our university. In recent years, a significant increase has been observed in the records of our foreign students. We are pleased to have started scientific studies in 2017 with MIA on increasing interest in Mode Implant products in our country.”



ASSOC. PROF. DR. YULIYA  
SLYNKO  
ORAL & MAXILLOFACIAL  
SURGERY DDS, PhD



WITTEN/HERDECKE UNIVERSITY, FACULTY OF HEALTH, GERMANY



# MIA GERMANY

ASSOC. PROF. DR.  
**HAKAN BILHAN**  
 ORAL & MAXILLOFACIAL  
 SURGERY DDS, PhD

## A Turkish Scientist in Germany

He is married and has 3 children. Dr. Hakan Bilhan graduated from Acetate University in 1993 and studied oral surgery at Karl-Franzens University in Graz, Austria. She completed her PhD at the University of Zurich, Faculty of Dentistry, and Department of Oral Surgery. She completed her PhD in Prosthetic Dentistry at Istanbul University Faculty of Dentistry between 1996 and 2004 and completed her PhD in 2012 at Bilkent University. He worked as an instructor. After working in Istanbul University for 18 years, he was the founding chairman and lecturer at Okan University Faculty of Dentistry, Department of Prosthodontics. In 2017, Hakan Bilhan moved to Germany and worked as a faculty member at Witten / Herdecke University and also in a private clinic. He has many national and international publications and presentations on mobile dentures, complete dentistry, dental implants and periodontology. Dr. Hakan Bilhan works with MIA academy.



## International Scientific Study

Witten University Faculty of Dentistry Department of Prosthodontics Assoc. Dr. Hakan Bilhan, Istanbul University Faculty of Dentistry, Department of Prosthodontics, Assoc. Dr. With the scientific study in the prim Implant Dentistry: The Official Journal of The International Congress of Oral Implantology prim, they have academically documented the success of the design of Mode RAPID implants in primary stabilization, and in particular the outstanding success of bone types in difficult stability. In this study, which is thought to be of great interest, it has been reported that even physicians who are interested in implantology can easily achieve primary stability thanks to this implant design.



**INDIAN DENTIST RESEARCH&REVIEW**

# MIA INDIA

My Dentistry Specialty Dental Conference & Workshop organized in Bangalore, India on 29-30th of April, 2017 the main sponsor of which was MIA, has attracted the attention of dentists with its scientific contributions.



The conference held at Alfot Whitefield Hotel with the presentation of one of the MIA speakers Dr. Fisnik Kasapi.

Moreover; our 1st Level Implant Master Workshop program was published in Indian Dentist magazine of Indian's Premier Dental Journal.



**Mode India**  
Mode Medikal India Private Limited Company was established in one of the world's largest population Maharashtra. MIA has been on its way to becoming more active in India.



GOCE DELCEV UNIVERSITY, MACEDONIA

# MIA IN THE INTERNATIONAL PLATFORM DICLE SYMPOSIUM HAS COME WITH THE PARTICIPANTS

6th International Symposium of TPID (TURKISH PROSTHODONTICS and IMPLANTOLOGY ASSOCIATION) was held between 2-4th of November 2018, at Dicle University Congress Center in Diyarbakir, and hosted local and foreign dentists. In the symposium with intense participation, guest lecturer of Mode Implant Academy was Prof. Dr. Kiro Papakoca. Our Lecturer had presented the subject about "Mode Implant Prosthesis Technique Complications in Dental Implantology." In his presentation, Prof. Dr. PhD Kiro Papakoca shared knowledge and experience, aiming to reveal the frequency and types of technical complications in implantsupported full dental fixed prostheses.

The most common complications that occur during dental implants are mechanical. The prosthetic conditions were determined by clinical analysis and radiographic examination. Design features of implant, abutment and prostheses, materials used and biomechanical issues have a significant impact on the results of these prostheses. Immediately after the first technique and the implantation of the implant, immediately after the biological complications, the fixed full dental prostheses for our toothless patients occur continuously over time due to fatigue and stress. The most common reported implant - prosthetic complication was screw fractures or hypertrophy - tissue hyperplasia. The combination of implant-bone anchor, screw fixation of the prosthetic components and the dynamics involved involve a complex load with frequent loosening and breaking of the components of implant-supported prostheses. These events may not lead to implant prosthesis failures, but the amount of repair and maintenance required for both the clinician and the patient is important in terms of time and cost. In his presentation, Papakoca reported cases



of interest by the participating dentists. In addition, "Surgical or Non-Surgical Treatment - Which Is More Functional Guided Bone Regeneration A New Concept: 3d GBR Technique u and u The Effect of Prosthetic Use on Elderly People on Cognitive Functions" will be presented to the experts in the field by making presentations on the important issues of dentistry they carried.

The Dicle Symposium, which brings together young teachers and young colleagues, has attracted a great deal of interest in MIA scientific publications. During this program which aims to raise awareness for new generations, conferences, workshops, oral poster presentations, presentations and technological developments in the field of prosthodontics and implantology were followed.



# MIA BALKANS

Since 2013, Dr. Fisnik Kasapi is international speaker of scientific programs, has been President of the Albanian Association of Implantology in Macedonia, and in 2014 he is also a committee member of the BDIZ EDI European Dental Implantologist Association.

## **IMPLANTATION AND AUXILIARY MATERIALS PRGF Techniques for Reconstructive Implant Treatment**

- Immediate implantation and details of single and partial tooth deficiencies
- Evaluation of autogenous and non-autogenous grafts (biomaterials)
- Crest expansion and upgrade
- Membrane applications
- The importance of planning and grafting by region
- Bone growth factors and accelerated bone regeneration



## **Contract with BDIZ EDI European Association of Dental Implantologists**

In February 2018, the BDIZ EDI European Association of Dental Implantologists executes a scientific association agreement in Cologne with Dr. Fisnik Kasapi. With this agreement MIA studies have gained the support of the European Dental Implantologists Association under international accreditation.



## **Macedonia-Based Balkans Coordination**

Since 2012, Mode Implant System are successfully presents in Balkans from the head office of Mode Medikal Balkans in Macedonia. Dr. Fisnik Kasapi is one of MIA international speakers and uses our system in his clinic more than 6 years.



Dr. Fisnik Kasapi was born in Skopje in Macedonia. Cyril and Methodius University graduated from the faculty of dentistry. Between 2001 and 2004, he specialized in Oral Surgery in Skopje. Dr. Fisnik Kasapi is a member of the Albanian Dentists Association since 1997, Albanian Association of Oral and Maxillofacial Surgery since 2004, the Albanian Association of Oral and Maxillofacial Surgery in Macedonia since 2007 and also he is a member of the board of directors of the Macedonian Society of Oral and Maxillofacial since 2010. Moreover; in October 2013 he was the chairman of the O.K. 3rd Panamanian Congress. Since 1998 he has run his own dental clinic.

# MIA MOSCOW

## 41th INTERNATIONAL DENTAL FORUM & EXHIBITION

MIA ahead with implantology in Moscow in 17-20th of April, 2017

MIA met with international participants and visitors of the dentistry sector in Dental Salon Exhibition, organized by Russian Dental Association.

MIA introduced training series “New Era in Implantology” with international visitors during this event. “New Era in Implantology” training program attracted Russian and other international dentists..



### Mode Implant Russia

In 2016 Mode Medikal Russia was established.

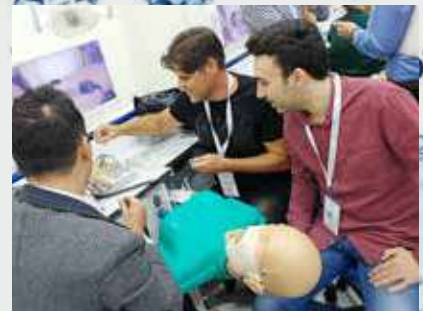

CHALLENGE  
YOUR  
KNOWLEDGE  
OF DENTISTRY  
WITH  
MODE IMPLANT  
ACADEMY

# PREFERENCE IN OVER 40 COUNTRIES WITH CONFIDENCE

MODE IMPLANT has wide International Sales Network with Main Head Office in Turkey, Branch Offices in India, Russia, Balkans and distributors in 24 countries.





# IDS EXHIBITION MIA EVENTS

MIA take place at the IDS International Dental Fair organized by Koelnmesse in Koln, Germany, every two years.

The academic and scientific training carried out with specialists in the Mode Implant booth was welcomed by the visitors of the fair. With our colleagues who have an opportunity to get to know the MIA, we have conducted consultations interactively. We would like to thank all visitors who visited our stand.



# AEEDC EXHIBITION MIA EVENTS



MIA brought a great attention with its hands-on applications as well as surgical and prosthetic trainings during the AEEDC Dubai Show, which held every year in Dubai.

In Dubai, MIA performed successful short trainings in terms of surgery and prosthetics with hands-on studies. Emphasizing the latest clinical cases in the field of dentistry, various dental products, equipment and services, as well as exhibition halls, interactive activities were held at the fair, and the presentations to the dentists visiting our stand were quite colorful.

## AEEDC DUBAI 2018



## AEEDC DUBAI 2017





## MIA IN IDEX 2018...

IDEX 2018, which was held 12-15<sup>th</sup> of April 2018; Mode Implant Academy has made its mark in the fair with its scientific activity! MIA LIFE took its place in the first issue of the expected academic journal with the intense participation.

The IDEX exhibition, known as the third largest organization in the world, took place with the participation of 6 thousand 152 visitors. Mode Implant Academy came together with dentists from different parts of the world and gave information about the activities of the academy.

In April, MIA Life Magazine was the focus of attention of local and foreign dentists. The physicians who had the opportunity to examine the cases in the journal became familiar with MIA. Mode Implant Academy During the 4-day exhibition; He organized a training program covering various topics such as Regeneration Approaches, Maxillary Orientation, Not Measuring and Mowing. In the training program held in 8 sessions; Dr.Guvenc Uz, Dr. Sabri Sencan, Dr. Volkan Arici, Dr. Selhan Kaya, Dr. Ferhat Misir, Dr. Seda Ozturan, Dr. Defne Burduroglu, Dr. Tolga Sitalci, Dr. Ahmet Kigili and Dr. Ugur Meric information and fled to the participants were transferred on April 15th, Sunday.

On the other hand, the open session at the fair congress hall was met with great interest. It was an

interactive training on Sunday's scientific activity case studies with 45 people. In our scientific activity with an intense participation; our speaker physicians answered the questions of their colleagues and signed a successful event.



## IDEX 2018, MIA PROGRAM

### 12<sup>TH</sup> APRIL

14:30-15:00 **DR. GUVENC UZ**  
IMMEDIATE SOLUTIONS FROM FINAL  
TO START

15:00-15:30 HANDS-ON

16:30-17:00 **DR. SABRI SENCEN**  
IMPLANTOLOGY: FROM THEORY TO  
REALITY

17:00-17:30 HANDS-ON

### 13<sup>TH</sup> APRIL

12:30-13:00 **DR. VOLKAN ARICI**  
DUNGEON OF THE MAXILLA

13:00-14:00 HANDS-ON

14:30-15:00 **DR. A. SELHAN KAYA**  
IMPLANTOLOGY WITHOUT  
COMPLICATIONS

15:00-15:30 HANDS ON

### 14<sup>TH</sup> APRIL

12:30-13:00 **DR. FERHAT MISIR**  
4TH DIMENSION OF IMPLANTOLOGY

13:00-14:00 HANDS-ON

14:30-15:00 **DR. SEDA OZTURAN**  
REGENERATIVE APPROACHES

15:00-15:30 HANDS ON

16:30-17:00 **DR. DEFNE BURDUROGLU**  
IMPRESSION POINTS

17:00-17:30 HANDS-ON

### 15<sup>TH</sup> APRIL

13:00-15:00 **DR. UGUR MERIC / DR. TOLGA SITILCI  
/ DR. AHMET KIGILI**  
ALL ASPECTS OF IMPLANTOLOGY  
INDICATIONS/AUDITORIUM



# We're in British Dental Conference, in Birmingham ... DENTISTRY SHOW 2017 ENGLAND



MIA met with local and foreign dentists at Birmingham NEC on 12-13 May 2017, which was organized in cooperation with The British Dental Association and CloserStill Media.

MIA stand had intense attraction from the fair visitors to learn new skills, the dental industry's brightest leaders and well-known experts to get practical and concrete ideas.

Visitors of the Denstry Show in the UK, the largest dental show had the chance to see conference sessions of MIA Lectures.



## MIA EGYPT

# EGYPTIAN DENTAL SYNDICATE INTERNATIONAL CONGRESS



## 18<sup>th</sup> International Dental Congress Egyptian Dental Association Meeting (EDSIC 2017)

At the 18th International Dental Congress held in Cairo, Egypt between 22-24 November 2017, the MIA met dentists from various countries of the world. Academicians, scientists, clinicians and researchers from different countries of the Middle East showed great interest in the new CAG event in Implantology and the hands-on study that followed.

On Wednesday, November 22 The subject of the training given by Uğur Meriç was "Autogenous Bone Gold Standard Back In Daily Practice."



## Egyptian Dental Syndicate International Congress (EDSIC 2017)



The Egyptian Dental Professionals of the Egyptian Dental Association, Egyptian Dental Syndicate International Congress 2017 (EDSIC 2017); Okan University Department of Oral and Maxillofacial Surgery and MIA Speaker Asst. Assoc. Dr. Uğur Mercan attended as a speaker.

Dr. Prof. Dr. Uğur Mercan presented the subject "The Challenges of Implant Applications in Elderly (Geriatric) Patients and Recommendations on Clinical Solutions."



# GREAT ATTENTION TO MODE IMPLANT ACADEMY FROM RUSSIA DENTIMA KRASNODAR 2018

MIA attracted great attention at the International Dental Exhibition held in Russia on May 23-25, 2018 and shared the good news of future events with the visitors of the fair. Numerous records were received from physicians who received information about the New Era training series, which will be held in April and November in 2019.

Dentima Krasnodar Fair, Russia's leading dental exhibition, hosted a large number of visitors from all over the world in 2018. Our academy, which exchanges ideas with the incoming dentists, informed the dentists about the latest technologies.



# MODE IMPLANT ACADEMY PROVIDER OF CONTINUING DENTAL IMPLANT EDUCATION...

MODE MEDİKAL completed implantology courses in collaboration with IMPLANTDER (Dental Implant Industrialists and Businessmen Association, which was established by Mode Medikal as a lead of its field) and TDB (Turkish Dental Association) Academy, in 2017.

TDB realized over 100 local scientific activities during 2017 and 2018, the large part of them was performed by Mode Implant Academy.

This training courses lead to be a platform dedicated to the education and advancement of every auxiliary participant. Follow our web site to learn more about our previous course and be informed about our new trainings.

[www.miacademy.net](http://www.miacademy.net)



**TDB**  
İzmir Dişhekimleri Odası  
4 MART 2017  
14:00 – 18:00  
Tepeköle İş Merkezi Kat: D:209-210-211 Bayraklı/İZMİR  
☎ 0232 461 21 52  
☎ 0544 650 23 09  
☎ 0530 555 88 66  
MODE  
FİDİL & ŞİŞİ

4 MART 2017  
İZMİR  
Her Açılan İmplant  
**QUATROFIX**  
Doç. Dr. Mustafa Ramazanoğlu  
Köprüden Önce  
**SON ÇIKIŞ**  
Doç. Dr. A. Alihan Çiğdemir

**TDB**  
Güvenli ve Kaliteli Eğitim  
18 ŞUBAT 2017  
Diyarbakır  
LİLİZ HOTEL  
13:30 – 17:30  
Korkusuz Dişhekimliği  
MODE  
FİDİL & ŞİŞİ

**TDB**  
İzmir Dişhekimleri Odası  
20 MAYIS 2017  
14:00 – 18:00  
Tepeköle İş Merkezi Kat: D:209-210-211 Bayraklı/İZMİR  
☎ 0232 461 21 52  
☎ 0544 650 23 09  
☎ 0530 555 88 66  
MODE  
FİDİL & ŞİŞİ

20 MAYIS 2017 İZMİR  
ALTI ÜSTÜ İMPLANT ÜSTÜ PROTEZ  
& Klinik Yönetimi  
MIA  
☎ 0232 461 21 52  
☎ 0544 650 23 09  
☎ 0530 555 88 66

**TDB**  
Kahramanmaraş Dişhekimleri Odası  
1 NİSAN 2017  
12:00 – 16:30  
Kahramanmaraş Çarşamba Hotel  
☎ 0344 291 85 95  
☎ 0504 366 48 03  
☎ 0530 555 88 66  
MODE  
FİDİL & ŞİŞİ

1 Nisan 2017  
Kahramanmaraş  
REJENERATİF Yaklaşımlar  
Doç. Dr. Serdar Selçuk Özturan  
Sondan Başa  
**İMMEDİYAT**  
Doç. Dr. A. Alihan Çiğdemir

**TDB**  
Adana Dişhekimleri Odası  
11 MART 2017  
14:00 – 18:00  
Cemal Paşa Mah. 63006 Sk. İskenderpaşa April No:11 Kat:1 Seyhan/ADANA  
☎ 0322 457 24 67  
☎ 0530 919 29 18  
☎ 0530 555 88 66  
MODE  
FİDİL & ŞİŞİ

11 MART 2017  
ADANA  
İmplantın Yaşın Yok  
Prof. Doç. Dr. Uğur Mercan  
Köprüden Önce  
**SON ÇIKIŞ**  
Doç. Dr. A. Alihan Çiğdemir

**TDB**  
Antalya Dişhekimleri Odası  
22 NİSAN 2017  
14:00 – 18:00  
Antalya Dişhekimleri Odası Kat: 209-210-211 Kat:1 Seyhan/ANTALYA  
☎ 0242 237 52 52  
☎ 0507 283 18 70  
☎ 0530 555 88 66  
MODE  
FİDİL & ŞİŞİ

22 NİSAN 2017 ANTALYA  
ALTI ÜSTÜ İMPLANT ÜSTÜ PROTEZ  
& Klinik Yönetimi  
MIA  
☎ 0242 237 52 52  
☎ 0507 283 18 70  
☎ 0530 555 88 66

# MIA IN BELGRADE

In Belgrade, MIA added a new page to the information sharing ... The MIA held an important history in the dentistry with the education organized in Belgrade on May 18-21, 2017.

Our 4 days training with professionals from different provinces began with meet on 18th of May. Our limited education was held with the participation of 70 dentists. On the first day before the training, we visited the important historical and cultural places of Belgrade with our participating physicians.



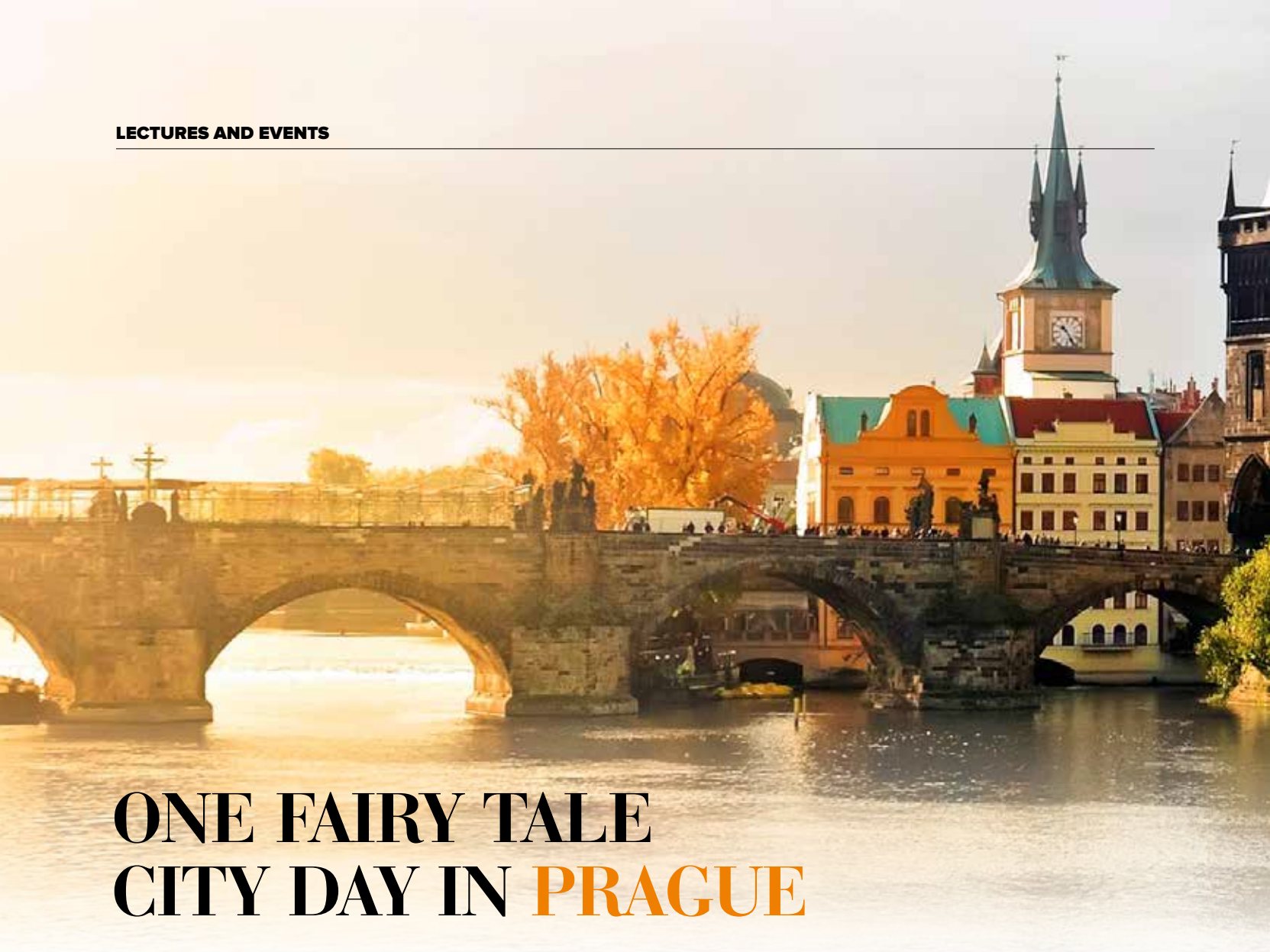
After the trip to Belgrade, our training began with Uğur Meriç, Oral & Maxillofacial Surgery. Dr. Uğur Meriç, simple autogenous bone collection methods and synthetic grafts without the need for all indications explained the applications. Dr. Uğur Meriç, who was continuing with the subject of Maxillary Sinus Anatomy and Sinus Lifting with Implant Application Protocols, informed all physicians in the question section.





Professionals who participated in our program in Belgrade, which is the biggest city of the Balkans, which has been a part of our history for a long time during the Ottoman Empire, traveled to history along with an efficient education. It was an unforgettable event for our dentists who watched the city from the fortress, where the Sava and Danube rivers met.





# ONE FAIRY TALE CITY DAY IN PRAGUE

We were in Prague, the capital of the Czech Republic, one of the largest and most important cities in Central Europe.

Dr. Seda Özturan with the presentation subject “Aesthetics in Implantology”, Dr. Fisnik Kasapi with the presentation “Implantation and Graft Materials”, and Dr. Volkan Arıcı’s presentation with “Sinus Lift Techniques and Implant Applications” we discussed during this event. The Prague event was completed by Dr. Muzaffer Erdoğan’s clinical case presentations.





**Art and Culture**

Combined with many art and aesthetics that have witnessed the Middle Ages, in Prague, we've endowed the friendship of the MIA with beautiful squares from the UNESCO-protected city square, the glorious Prague Castle, which has taken the Vltava River and the entire city under its seats.





## THE ANNUAL DENTAL CONGRESS & SWEDENTAL

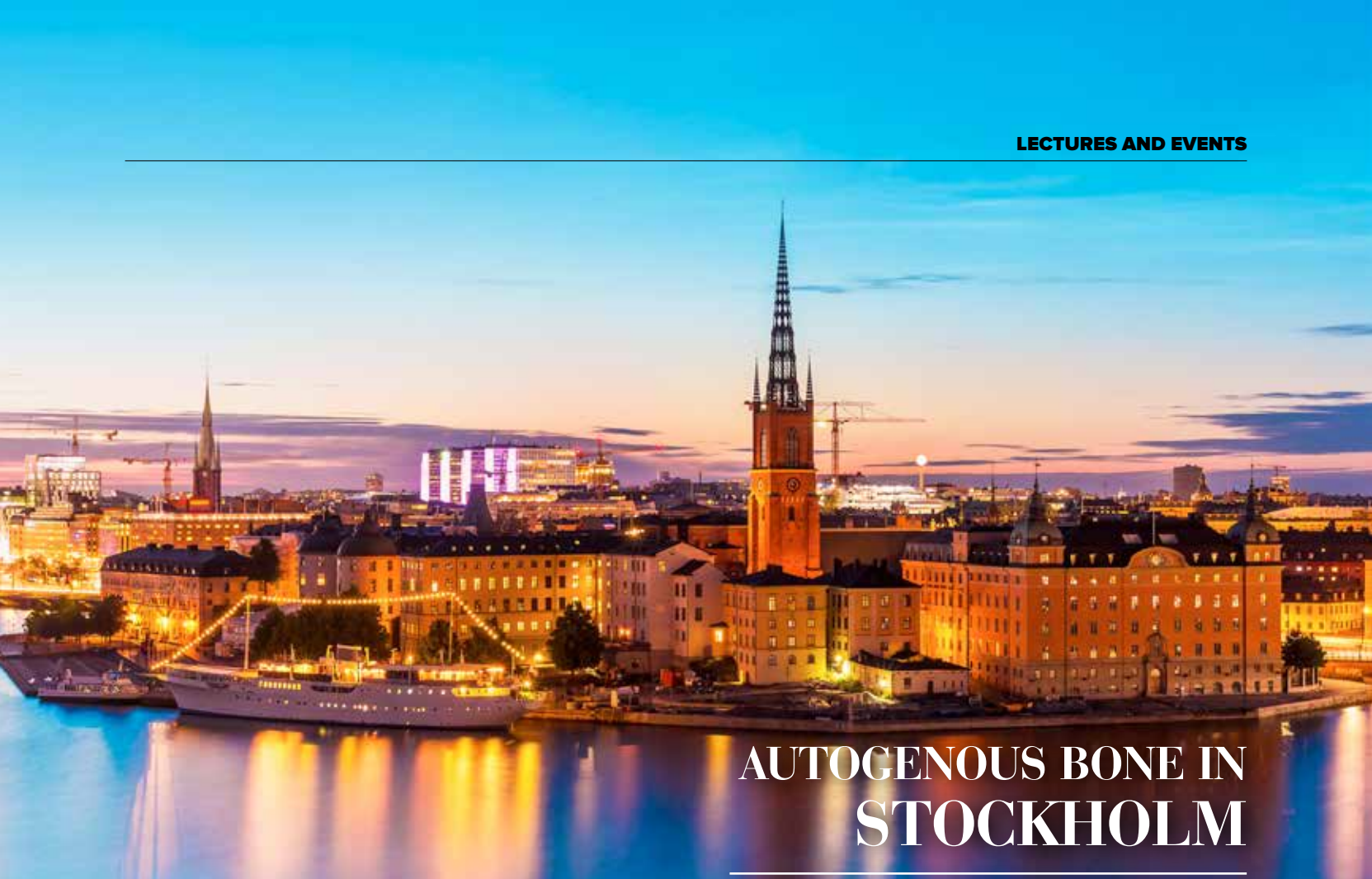The full-day training program, which was held in Stockholm immediately after the fair, has left its mark on the fair!

MIA met with Scandinavian countries at the SweDental Dental Congress held on 15-17<sup>th</sup> November 2017. MIA, which took part in the congress and fair event that hosted the most visitors of the Scandinavian countries in the international dental organizations, gave the good news of the Isk Implants Implantology and training event in Stockholm. In order to contribute to

the improvement of the professional knowledge of physicians and to improve their skills, the interest in the training programs organized by MIA was intense. The history and socio-economic identity of the dentists who visited the stand and the details of the training we will do in Stockholm, which is a very important city for Scandinavians, were recorded and many records were taken.

**THE STOCKHOLM IS A VERY IMPORTANT CITY IN THE HISTORICAL AND SOCIO-ECONOMIC IDENTITY FOR ISKANDINAVS. THE DETAILS OF THE TRAINING PROGRAM WHICH HAD HELD AFTER THE EXHIBITION WERE SHARED.**





## AUTOGENOUS BONE IN STOCKHOLM

Immediately after the three-day Swedental Fair in Sweden, which was important for the dental industry, MIA gave dentists from Scandinavian countries a full-time training program in Stockholm.



Dr. Uğur Meric completed course with subject "Autogenous Bone as a Gold Standard" explained the applications that could be performed for predictable long-term clinical success in implant dentistry, he informed the participants from various countries by reintroducing the autogenous bone in the clinical practice by dentists.



LET'S MEET WHERE  
THE CONTINENTS MEET...



Dear Dentist, Let's meet where the continents meet for  
"NEW ERA IN IMPLANTOLOGY COURSE" programs in Istanbul for 3 days...



## NEW ERA in IMPLANTOLOGY COURSE PROGRAM

- ▶ COURSE
- ▶ HANDS-ON
- ▶ CERTIFICATE

MIA MODE IMPLANT ACADEMY COURSE PROGRAM WITH SURGICAL AND  
RESTORATIVE HANDS-ON PROCEDURES

### PROGRAM

#### 1<sup>st</sup> DAY

Arrival to Istanbul & Check-in

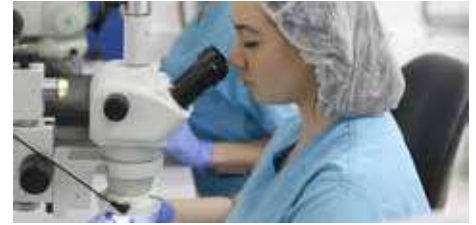- 11:00 City Tour
- 13:30 Lunch
- 14:00 Historical Place
- 18:00 Free Time

#### 2<sup>nd</sup> DAY ADVANCED IMPLANT SURGICAL PROGRAM

- 09:00 Opening
- 10:00 Implant Surgery Lecture 1
- 12:00 Lunch
- 13:30 Implant Surgery Lecture 2
- 15:30 Surgical Hands-On
- 19:00 Bosphorus Boat Tour & Dinner

#### 3<sup>rd</sup> DAY ADVANCED IMPLANT PROSTHETIC PROGRAM


- 09:00 Mode Implant Factory Tour & Presentation
- 11:00 Implant Prosthesis Treatment Lecture
- 12:30 Lunch
- 14:00 Restorative Hands-On
- 19:00 Turkish Night Show & Gala Dinner



PROF. DR. HASAN MERİÇ  
PERIODONTOLOGY DDS, PHD



DR. UĞUR MERİÇ  
ORAL MAXILLOFACIAL SURGERY DDS, PHD



DR. ÜLKEM CÜRAL  
ORAL MAXILLOFACIAL SURGERY DDS, PHD



DR. AHMET KIĞILI  
PROSTHODONTICS



DR. DEFNE BURDUROĞLU  
PROSTHODONTICS



DT. FARIBA KHAYATI  
TECHNICIAN



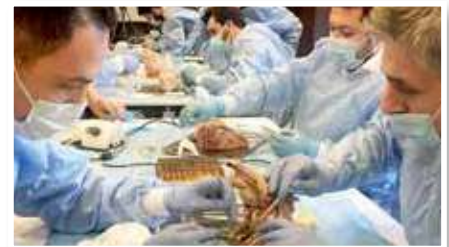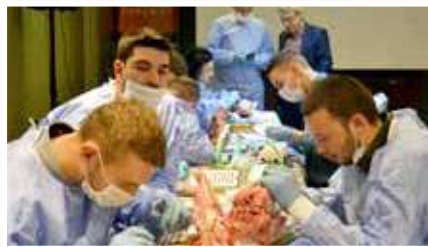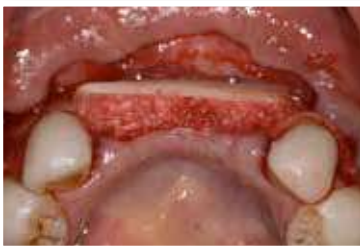### IMPLANT SURGICAL PROGRAM

## AUTOGENOUS BONE “GOLD STANDARD” BACK IN DAILY PRACTICE...

DR. UĞUR MERİÇ & DR. ÜLKEM CÜRAL

Even if the Autogenous Bone is accepted as a “Gold Standard”, usage in our daily practices is very limited. Difficulties in acquiring sufficient quantity of the material, needs a secondary surgery and probable resorptions possibilities are the prejudices for the clinicians avoiding autogenous bone in their daily practices. The philosophy indications and application of autogenous bone from simple to complex cases will be discussed in this presentation. Techniques of collecting autogenous bone by drilling without saline.

Usage of Autogenous Bone in practice.



### ADVANCED IMPLANT PROSTHETIC PROGRAM

## PARADIGM SHIFT IN LONG TERM SUCCESS AND HYBRID PROSTHESIS...

DR. AHMET KIĞILI & DR. DEFNE BURDUROĞLU & DT. FARIBA KHAYYAT

Success by design not by chance. Implant abutment selection; type, design, and material. Advantages of the Conical Connection type systems. Screw-retained versus cement-retained implant restorations. Journey through the process of the treatment planing, temporization, managing abutments, taking impression and delivering the final prosthetics. Implant impression techniques... Treatment concepts for the restoration of the edentulous jaws. Hybrid solutions Laboratory communication and collaboration.

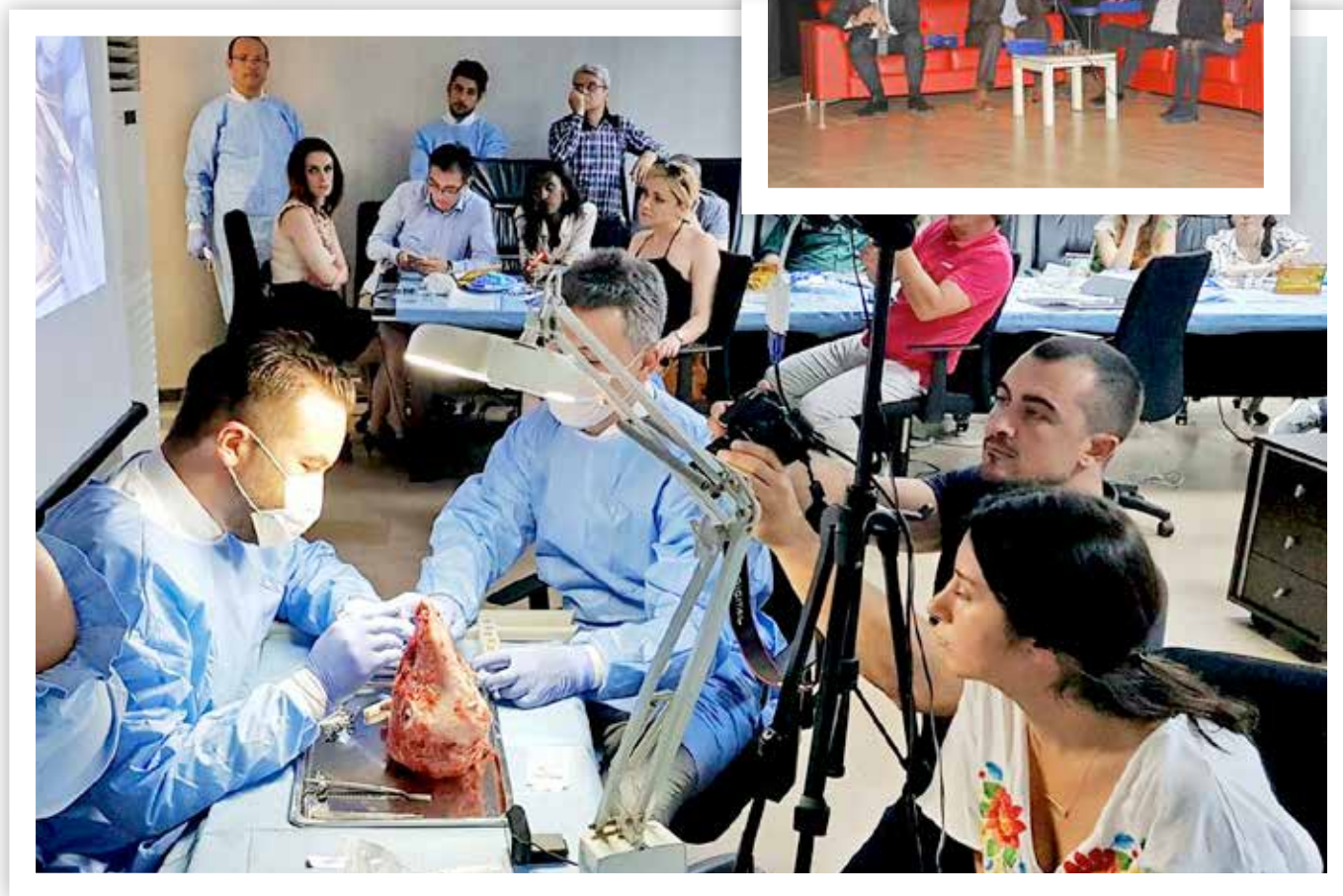
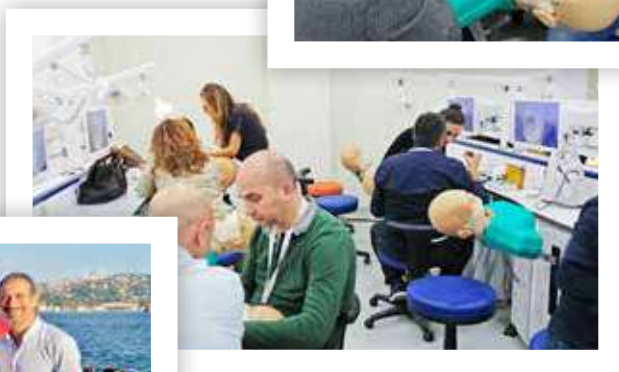
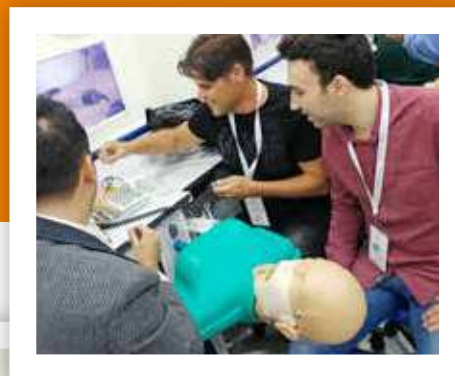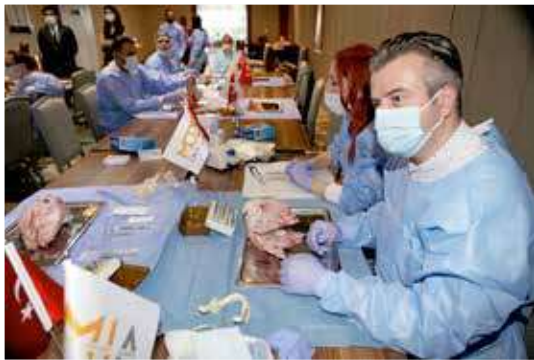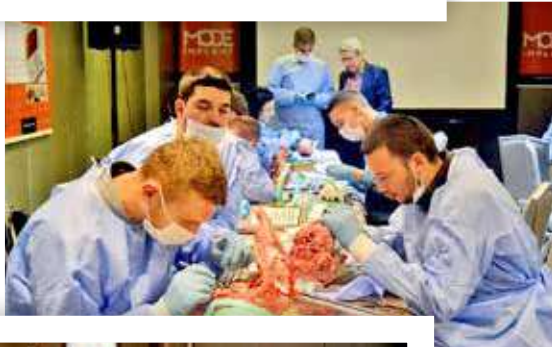For coming courses please follow our website: [www.miacademy.net](http://www.miacademy.net)



# MOMENTS FROM NEW ERA

Totally 12 "NEW ERA IN IMPLANTOLOGY" Courses in 3 years...







## GROUP COMPANIES POWER...

Experience and confidence with third generation of industrialists' family...

Mode Medikal is a part of Akmakina Corporation Group Companies that takes place in the international industry sector for more than half century.



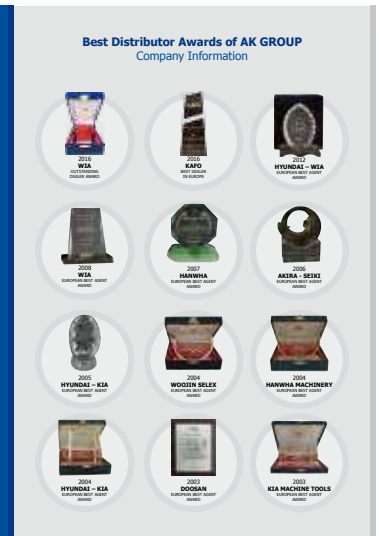1965



1975



1980



## INTERNATIONAL AWARDS IN 54 YEARS...

Ak Makina was established in early 1981 as a trader of “used” CNC machines from Europe. From 1988, Akmakina became one of the first company-supplier of CNC machines tools to Turkey and other countries and now it is a Leader supplier in Turkey.

We provide great benefits to the development of Turkey industry today by adding World's leading brands of CNC machines in industry. Every year Akmakina add new awards from its Worldwide suppliers as a “BEST DISTRIBUTOR”.



## MODE MEDIKAL CELEBRATED 10<sup>TH</sup> YEAR ANNIVERSARY

Mode Medikal, under the leadership of Oguz Akyuz, has been established in 2008 and last year celebrated its 10 year anniversary. In the end of 10th year, the products of Mode Medikal present in over than 40 countries. The importance of 10th year for Mode Medikal was crowned by Award from USA as "The Manufacturer of the Year", and celebrated with big organization which was held on 7th-8th of September in Istanbul.

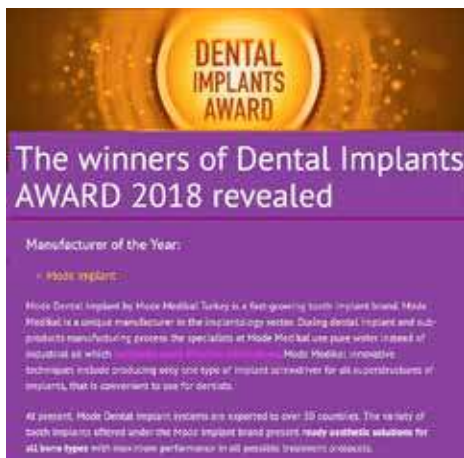
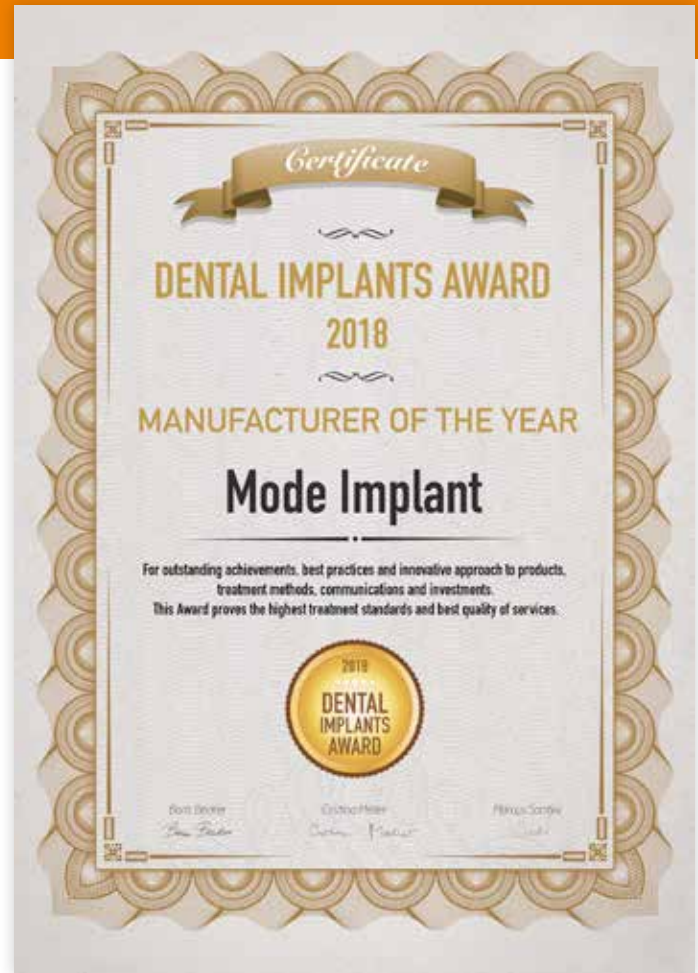
# PROUDLY IN OUR 11<sup>th</sup> YEAR

## “THE MANUFACTURER OF THE YEAR” AWARD FROM USA

International Health Organization by IVF Media America in 3 main and 8 sub-categories on behalf of the world-wide research found 8 award winners.

Mode Implant crowned its' success by this International Award in its' 10th years. We are proud of making a difference with our technological superiority among other global brands.



## 2018 DENTAL IMPLANT AWARDS WINNERS ARE ANNOUNCED

Mode Implant Turkey is a fast – growing tooth implant brand and a unique manufacturer in the implantology sector. During manufacturing process, the specialists at Mode Medikal use pure water technology instead of industrial oil which facilitates more effective sterilization. Mode Medical innovative techniques include producing only single type of implant screwdriver for all superstructures of implants.

[www.dentalimplantsfriends.com/winners-dental-implants-awards-2018-revealed/](http://www.dentalimplantsfriends.com/winners-dental-implants-awards-2018-revealed/)

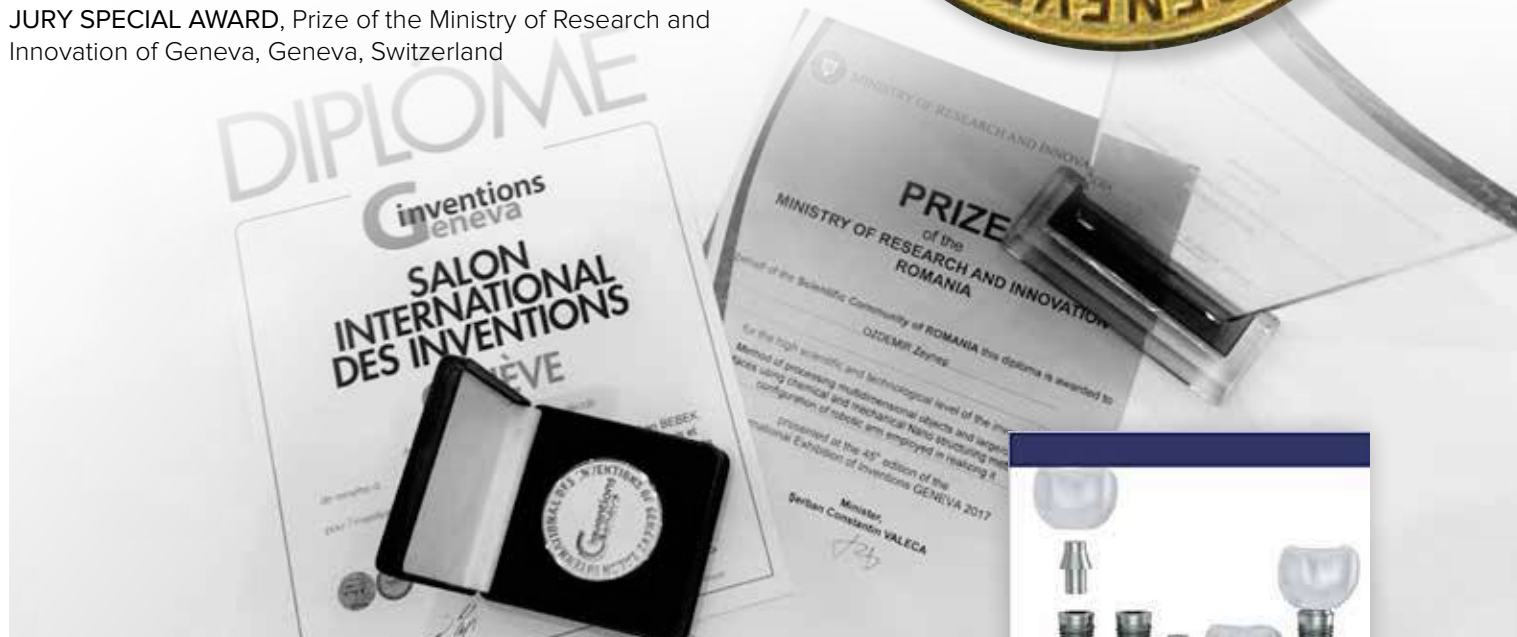# THE AWARDS FROM USA AND SWITZERLAND

## GOLD MEDAL RESEARCH AND INNOVATION AWARD GENEVA SWITZERLAND

GOLD MEDAL AWARD, 45th International Exhibition of Inventions of Geneva, Geneva, Switzerland, IP: 2013/15577

SILVER MEDAL AWARD, ISIFvention17, 2nd Istanbul International Invention Fair, Istanbul, Turkey IP: 2013/15577


JURY SPECIAL AWARD, Prize of the Ministry of Research and Innovation of Geneva, Geneva, Switzerland



## GENEVA SCIENTIFIC SUCCESS AWARD

“To be able to make the surfaces of implants either rough or smooth according to the needs by using nano-sized processing technique which are especially used in tooth, hip or heart, and also minimize the possibility of tissue rejection of the implant”

<https://doi.org/10.1016/j.msec.2016.06.002>



**NEW  
PRODUCTS  
DLC**



## DIAMOND LIKE CARBON COATING

**With DLC Coating Technology,**

- Harder wear, application number / life is increased,
- Friction coefficient decreases by 5 times, prevents overheating,
- Black Anti-Glare glare / reflection blocking, clearer appearance
- Excellent wear protection and high heating resistance
- Diamond-like carbon (DLC) coatings are perfectly suited to the highest abrasion conditions and high shear rates, even without lubrication.
- They also minimize friction losses
- DLC provides excellent protection against abrasion, tribo-oxidation and fusion wear and provides resistance to rapid wear and high pressure at low speeds



## DLC and TiN Coating Technologies

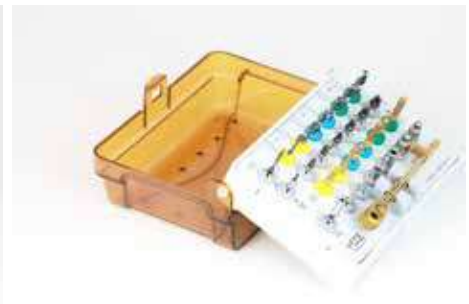Carbon coated drills 5 times lower friction coefficient



**PCS**



**SCS**



**HCS**

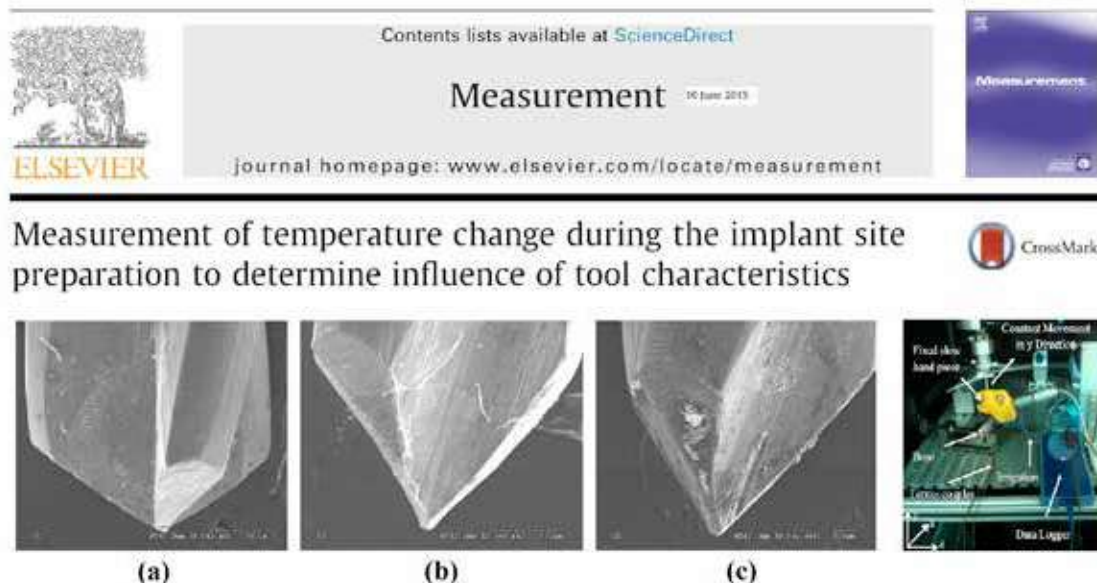


Fig. 4. SEM images of tool; (a) new tool, (b) 45 times used tool and (c) 90 times used tool.

## Measurement of temperature change during the implant site preparation to determine influence of tool characteristics

Journal of the International Measurement Confederation (IMEKO) 2015

### Abstract

Implant site preparation procedure is the most important factor that affects early osseointegration performance of a dental implant. During the site preparation procedure increase in the bone temperature above critical limit causes irreversible osteonecrosis. This heat rise compromises implant area around implants thus ending with unsuccessful osseointegration outcomes. In this experimental study drill tip geometry, drill tip angle and drill sharpness affects on procedure temperature were investigated. Experiments were carried on fresh bovine bones and implant sites were prepared individually for each experimental set.

### Conclusions

In this experimental study the purpose was to investigate the thermal changes produced by 3 individual drill tip angle, in different usage condition. Three different drilling speed evaluated with and without irrigation and thermal change was monitored

### Acknowledgements

The authors would like to thank Mode Medical and TESTO companies for their experimental set up and tool support.

Volume 79, February 2016, Pages 354-359

<https://www.sciencedirect.com/science/article/pii/S0263224115003115>

<https://pdfs.semanticscholar.org/1b63/1f7262b5f225732fb355ab452a7aedfd899a.pdf>



## HIGH PRIMER STABILIZATION WITH **MODE RAPID IMPLANT**

The design of the RAPID implant is an excellent option for all kinds of indications and especially in areas with reduced bone amount and quality, with the ability to condense spongiform bones, apex feature for immediate implantation protocols, ability to change direction during implantation.

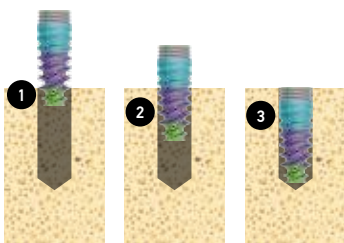

- Expanding Groove Section and High Primer Stabilization
- Reinforced Self Tapping Osteotomy
- Double Threaded Tooth Design and Rapid Implantation
- Constricted Coronal Structure and Minimization of Cortical Stresses
- Self Drilling Capability with Constricted Apex Structure
- Ability of Changing Direction in Soft Tissue
- Bone Condense Feature

**IMMEDIATE  
IMPLANTATION  
&  
IMMEDIATE  
LOADING**

High Primer Stabilization Capability  
even in Spongy Bones

**RAPID IMPLANT** High primary stability and strengthened self-tapping feature with expanding groove section and tooth root design.

The enlarged conical implant body gradually condenses bone with bi-directional groove design and allows minimal osteotomy resulting in minor traumas in the bone and surrounding tissues



Reinforced Self Tapping Osteotomy

High primer stability with the expanding groove section and tooth root design, self drilling capability with self-tapping and constricted apex structure.





## Is clinical experience important for obtaining the primary stability of dental implants? An ex vivo Study

Turkish Prosthodontics and Implantology Association

Journal of Prosthetic Dentistry 02 Oct 2018

### Abstract

The skill and experience of the clinicians in maintaining implant stability is rarely evaluated in the literature. The aim of this study was to investigate the clinicians' experience on maintaining the primary stability of implants with aggressive threads belonging to a novel dental implant system.

### Methods

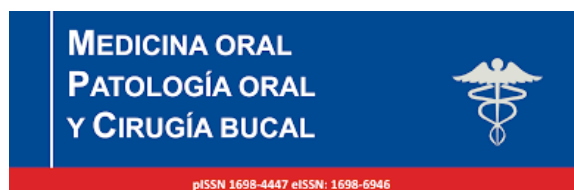
Three hundred implants with aggressive threads were inserted in fresh bovine ribs mimicking Type IV bone by five clinicians which were classified according to their previous experience of total number of implant insertion as follows: 1- expert 2-qualified 3- good 4- novice 5- non-experienced. After 30 implants were inserted into the ribs; the remaining 30 implants were inserted one day after by each clinician in order to measure the effect of one day of experience of the novel system on stability. An independent examiner measured the primary stability of all implants after insertion by using resonance frequency analysis (RFA), electronic percussive testing (EPT) and removal torque methods.

### Results

Negative correlations were found between EPT and removal torque and RFA (83.3% and 59.6% respectively;  $p < 0.05$ ); whereas a positive correlation was found between RFA and removal torque (73.8%;  $p < 0.05$ ). No significant differences were detected between the stability values measured by the clinicians ( $p > 0.05$ ) except the Periotest values (PTVs) of the unexperienced clinician. PTVs of the unexperienced clinician were significantly higher than the PTVs of the expert and good clinicians ( $p < 0.05$ ). Significantly higher stability values were detected in the secondary insertion of the non-experienced clinician as compared to her initial insertion values ( $p < 0.05$ ).

Acknowledgements: The authors would like to thank the owners and employees of Mode Medical who served the implants and the surgical sets without any problem to the clinicians that worked in this project

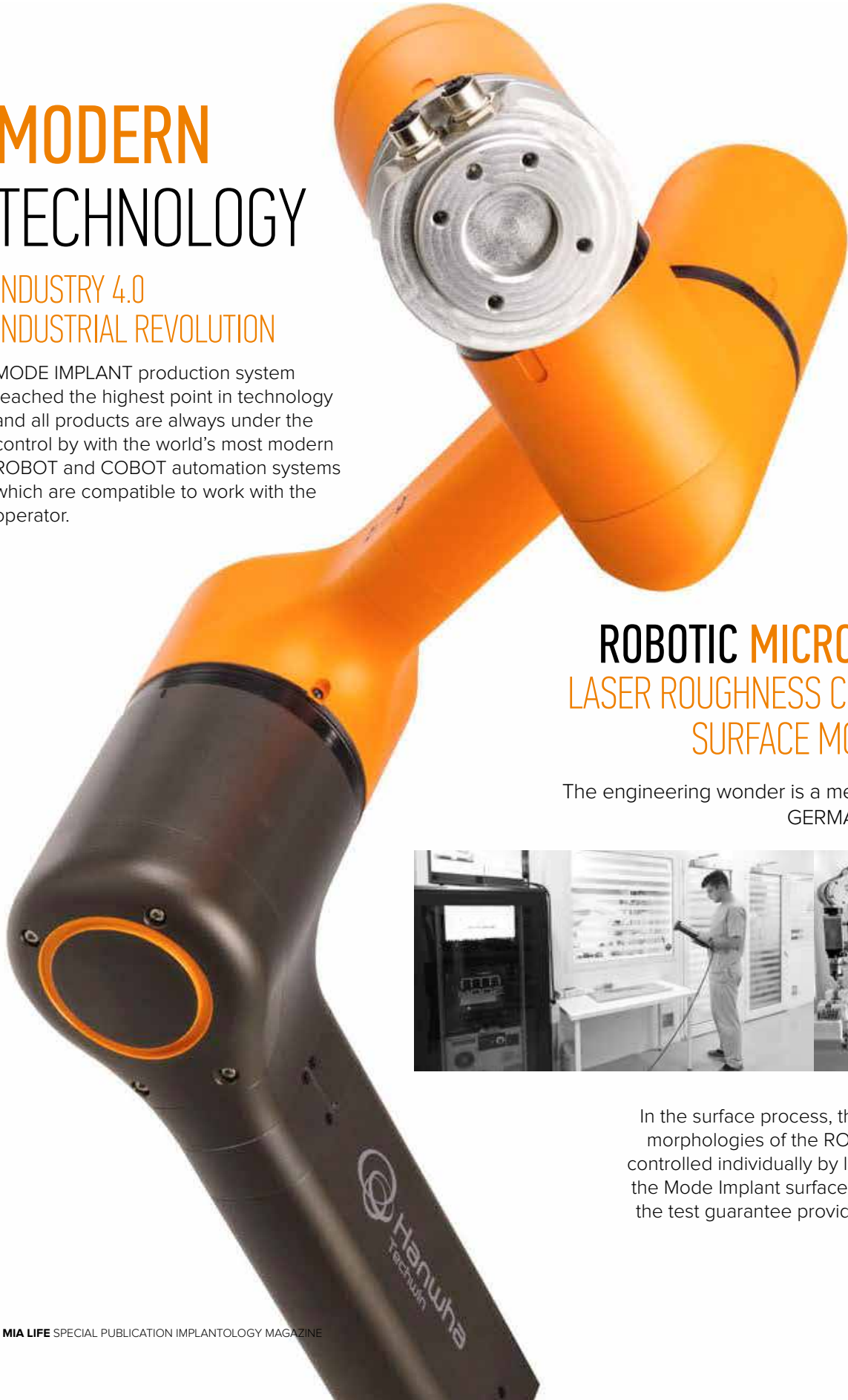<http://www.tpiddiyarbakir.com/files/kitapcik.pdf>



# MODERN TECHNOLOGY

## INDUSTRY 4.0 INDUSTRIAL REVOLUTION

MODE IMPLANT production system reached the highest point in technology and all products are always under the control by with the world's most modern ROBOT and COBOT automation systems which are compatible to work with the operator.



## ROBOTIC MICRO BLASTIC LASER ROUGHNESS CONTROLLED SURFACE MORPHOLOGY

The engineering wonder is a meet of JAPAN and GERMAN Technologies.



In the surface process, the implant surface morphologies of the ROBOT software are controlled individually by laser cameras and the Mode Implant surfaces passing through the test guarantee provide a perfect Bone-Implant contact.



Contents lists available at [ScienceDirect](http://ScienceDirect)

## Materials Science and Engineering C

journal homepage: [www.elsevier.com/locate/msec](http://www.elsevier.com/locate/msec)



Application of chemical mechanical polishing process on titanium based implants  
14 January 2016



### Application of chemical mechanical polishing process on titanium based implants

#### Abstract

Modification of the implantable biomaterial surfaces is known to improve the biocompatibility of metallic implants. Particularly, treatments such as etching, sand-blasting or laser treatment are commonly studied to understand the impact of nano/micro roughness on cell attachment. Although, the currently utilized surface modification techniques are known to improve the amount of cell attachment, it is critical to control the level of attachment due to the fact that promotion of bioactivity is needed for prosthetic implants while the cardiac valves, which are also made of titanium, need demotion of cells attachment to be able to function.

#### Materials and Methods

The original titanium foil sample surface, which is considered as baseline in this experimental study, was annealed. Fig. 1a illustrates the optical micrograph of the anodized titanium plate surface (200X) as well as the SEM cross sectional image illustrating the thick and porous oxide layer with 30–40  $\mu\text{m}$  thickness. Fig. 1b shows the titanium based dental implant used to implement the optimized CMP conditions through hand polishing on a 3-D sample. The dental implants were provided by MODE Medical Company and they were only shaped by machining prior to their exposure to the CMP testing.

#### Summary And Conclusions

In this study we introduced CMP process as an alternative technique to engineer the titanium based implant surfaces to induce smoothness or controlled surface roughness while simultaneously forming a protective oxide layer. The cell growth was observed to be affected more by the surface roughness and the cell attachment results have illustrated that there is an optimal roughness value where the cells are better adhering on the implant surface when their size match the surface structure better. Furthermore, HA attachment results also confirmed that the CMP treated surfaces tend to help the HA deposition more than an oxidized surface although the surface roughness values were comparable. In conclusion, CMP is a synergistic technique that can be implemented on the metallic implants by simultaneously forming a protective oxide layer, limiting bacteria growth, controlling cell attachment as well as promoting the attachment of biocompatible coatings.

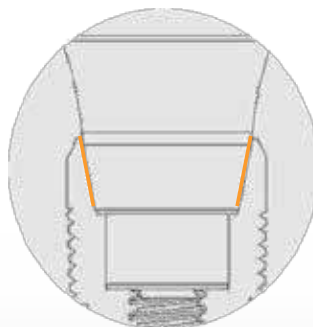

#### Acknowledgements

The authors would like to acknowledge the support from the European Union FP7 Marie Curie IRG (FP7-MC-IRG, NANO-PROX), The authors also would like to extend their appreciation to MODE Medikal for providing the dental implants.

<https://www.nanomagnetism-inst.com/usfiles/files/Articles/Ambient-AFM-MFM/AFM42.pdf>


# INTERNAL CONICAL OCTAGON CONNECTION

- Conical Implant-Abutment connection system distributes point forces formed by overload stresses on conical surfaces.
- The conical connection that balances the force distribution increases the resistance to bending and bending moments and reduces the risk of bone resorption.
- The design, which exhibits a perfect mechanical connection, centers the implant-abutment relationship and minimizes the loads that will come to the connecting screw.



**IMPLANT ABUTMENT  
EXCELLENT COMPLIANCE**

MODE IMPLANT LEVEL, RAPID,  
BONE, TISSUE and SHORT  
models all have Conical Octagon  
Connection Structure.



## COLD-WELD FRICTION COLD-WELD EFFECT



The MODE IMPLANT-ABUTMENT unique conical connection provides excellent overlap with the Micro Leakproof Cold Weld effect.



The MODE IMPLANT system's 1.5mm long tapered connection makes a significant difference compared to its competitors.



## Çukurova University Faculty Of Dentistry

### Dynamic and Static Load Performance of Implant Systems with Conical Implant-Abutment Connections

In recent years, dental implants have been used extensively in treating tooth loss. The stability of the implant-abutment interface is an important factor that influences load distribution to the marginal bone and internal conical connections have been introduced to provide the stability between implant and abutment.

The aim of this study is to compare the fracture strengths of implants with internal conical connection after different dynamic loading cycles. Implants (n:27) were centrally embedded in a polyacetal cylinder with an inner diameter of 20 mm and a height of 30 mm.

The implants were centered in the cylinder according to ISO 14801 as simulated bone loss of 3mm from the implant platform. All abutments were placed on the corresponding embedded implants, and the screws were tightened according to the manufacturers recommendations.

One implant for each brand were separated for SEM analysis. A hemispherical loading device made of cobalt-chromium alloy was manufactured and seated onto the unmodified abutments. The distance from the center of the hemisphere to the top face of polyacetal cylinder was standardized at 11 mm.

Three implants were used to determine the endurance limit. Then all brands were subdivided into four subgroups (n=6), 3 subgroups for dynamic + static loading (test groups; DTI-250, MODE-250, Imp-250, DTI-1000, MODE-1000, Imp-1000, DTI-2500, MODE-2500, Imp-2500), and 1 subgroup for static loading (control group; DTI-0, MODE-0, Imp-0.). The tests were performed by applying a compression load. Dynamic loadings were performed at 3 different cycles; 250.000, 1.000.000, 2.500.00 with 2N preload, with the endurance limit result loads as the upper load limit at frequency of 10 Hz for test groups (n=6). After dynamic loading, static loading was performed with a 5mm/min crosshead speed. Specimens were loaded until failure and all data's were recorded. Results were analyzed statistically.

As a result, statistical differences were found between the implant brands fracture strenght results after dynamic loading.

<https://tez.yok.gov.tr/>

Thesis No : 461143

2017

## THE BASIC REASON OF SCREW LOOSENING IS IMPLANT-ABUTMENT CONNECTION GEOMETRY

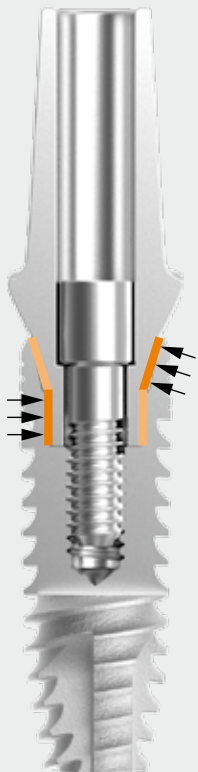
The implant-abutment attachment geometry lies at the base of the screw fracture and loosening problems.

Abutment screw fracture is one of the complications frequently encountered in implant applications.

This problem, which is of great importance by dentists, can be eliminated by removing the broken screw or by more applications on the tooth.

Generally, screw fractures occur as a result of a higher burden on the implant called occlusal trauma. This occlusal force can cause loosening of the screw inside the abutment.

One of the main reasons for loosening is not the fact that the screw is not robust enough to withstand this resistance, but is due to the fact that the implant abutment connection used is not of geometry that can distribute marginal loads.



At this point, the abutment and screw used for the implant must be fully compatible with each other. The screw loosening or fracture risk as a result of occlusal trauma is reduced to a minimum in screw and abutments that provide perfect fit.

The screw known to be compatible is the key point of a perfect implant application by ensuring that the resistance is evenly distributed at all points where it comes into contact with the geometric shape in the abutment.

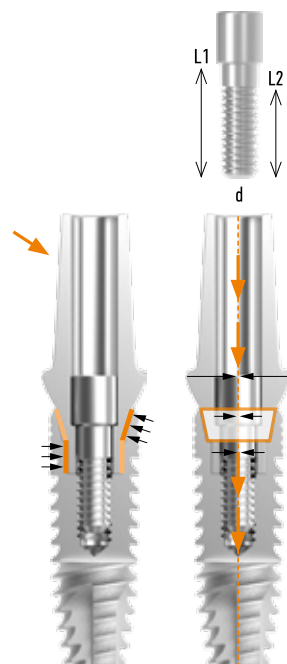
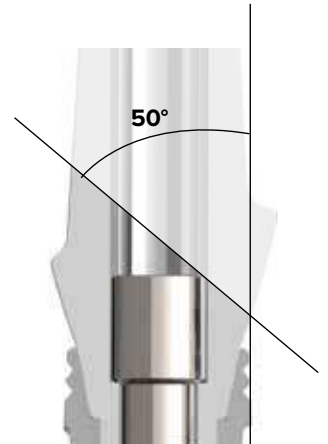
## MAXIMUM RESTORATIONS WITHOUT RESTRICTIONS

Excellent connection design with maximum restoration. The length and position of the abutment connection screw directly affect the restoration possibility in short-crown implant treatments with no occlusal distance.

The higher the upper position of the abutment connection screw, the higher the crown restoration height.

The most important factor is the need for maximum restoration for deep veiled closures especially in cases of bruxism as occlusal risk factor.

The limitation of the MODE IMPLANT-ABUTMENT fixing screw at the implant level offers the possibility of restoration at approximately 50° to the abutments and provides a great opportunity to make the shortest crown.



Morse Taper Implant-Abutment conical connection system decomposes the points forces, consists of overloading stresses, to the conical surfaces.

Perfect mechanical connection design minimizes the possible load to the center and connection screw in Implant-abutment correlation.



**YEDITEPE UNIVERSITY  
FACULTY OF DENTISTRY &  
DENTAL HOSPITAL**



## Comparison of Implant Abutment Breaking Values

T.C. Yeditepe University Health Sciences Institute Prosthetic Dentistry, İstanbul, 2014

Implant treatment is used frequently and successfully in one tooth loss, partial and complete tooth loss. Despite the implant therapy's advantages, dentists has some problems because of the mechanical and biological complications.

This subject's aim is to see the breaking values of the implants and abutments and compare them. Totally 40 implants, abutments and screws are divided into 4 different groups. ISO 14801 standard is used and implants are placed with 30 degree angle to transition piece. 25 N torque moment is calibrated by using the company's implant devices.

Instron Universal test machine applied an increasing force until the breaking happens with the speed of 8 mm per second. This process is applied to 40 implants one by one. Breaking values and breaking spots are saved.

Datas are statistically evaluated by using student t test and oneway anova test. As a result, solid abutments' mean breaking value (2350N) is higher than digital abutments' (1089 N). 4.5 mm platform diameter abutments' mean breaking value (1753 N) is higher than 3.5 mm platform diameter abutments' (1685 N).



1. Bone Implant  
Direct Abutment  
Abutment Screw



2. Instron Implant-Abutment  
Fatigue Test  
ISO 14801



3. Abutment Broken Average  
Force 1089N



4. Fracture (Abutment Level  
Broken)  
Abutment Screw & Implant  
Undeformed

Totally 40 implants, abutments and screws were provided by Mode Medikal

<https://tez.yok.gov.tr/>

Thesis No : 429165

2014



## ONE OF THE FACTORS DIRECTLY CONTRIBUTING TO IMPLANT SUCCESS IS THE QUALITY OF TITANIUM RAW MATERIAL.



MODE implant is manufactured with high quality titanium raw material of American Dynamet Carpenter Technology Holding, which is the choice of global implant manufacturers with its 125 years of experience.

**CP Ti (Grade 4)** Non-Alloy Pure Titanium Certified

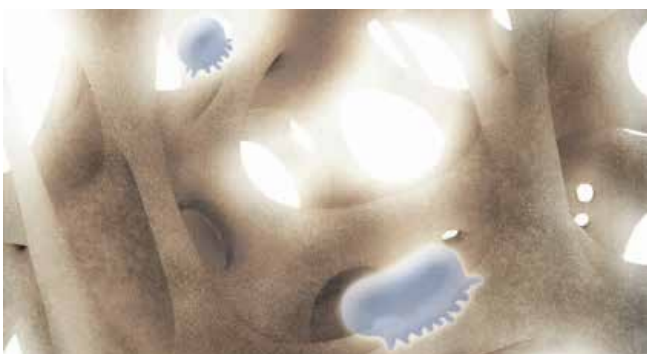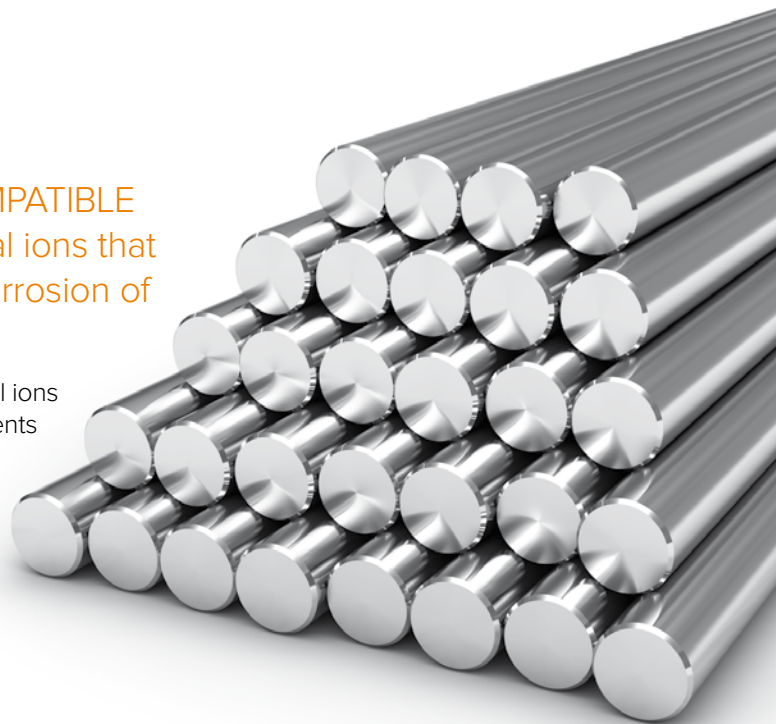**EDDY CURRENT** (Crack Control Test) Warranted

## SCIENTIFIC APPROACH GRADE4 PURE TITANIUM

GRADE 4 titanium materials are 100% BIO COMPATIBLE PURE materials that don't contain any additional ions that enter the body as a result of dissolution and corrosion of the surface film.

The dissolution and corrosion of the surface film causes additional ions to enter the body and the possible toxic effect of these ions prevents the use of materials in the body. The release of vanadium into the body in Ti6Al4V (GRADE 5) alloys can produce toxic (unhealthy / toxic) effects. Excessive amounts of metal ions release from an implant lead to mechanical damage to the implant as well as biological side effects.

(GONZÁLEZ and MIRZA-ROSCA, 1999).



### Perfect BIC Bone-Implant Contact

Mode Implant products which are blasted by the USA originated Biphasic Calcium Phosphate Micro - Blast Technology with HA futures have strong osseointegration and our implants have the morphology which allows osseointegration in a short time by supporting mechanical fixation.

By the excellent reaction between calcium ions and bone tissue, it provides perfect bone-implant contact during the optimum osseointegration process.



## Measurement And Image Processing Evaluation Of Surface Modifications Of Dental Implants G4 Pure Titanium Created By Different Techniques 2015 AIP Publishing LLC.

### Introduction

Compared to the conventional pure Ti-Grade 4 surface, many different surface topography modifications are applied in order to improve bone and implant interactions.

In this experimental research, the specimens were made from 6 mm cylindrical Grade 4 titanium (ASTM B 348, ISO 5832/2)

### Conclusions

Image processing method analysis suggested that there are critical topographical differences on the individual treated dental implant surfaces. From the SEM image-FFT analysis the macroscopic structure of TiO<sub>2</sub> Blasted+ Acid Etched surface founded to be smoother from other groups.

The roughest surface observed from the third group biphasic calcium phosphate ceramic blasted surfaces. It is assumed that increasing grain size of the blasting material resulted in increased roughness of the surfaces, but also caused different topographical characteristics. Blasted titanium surfaces exhibited an irregular rough morphology. It can be deduced from SEM images BCP surfaces and TiO<sub>2</sub> blasted surfaces exhibit similar irregularities but BCP surface images showed wider cavities 10-25  $\mu\text{m}$  produced by the blasting process in which micro pits, about 300  $\mu\text{m}$  in diameter.

In the macron level not irregular substantial flat areas identified which means homogeny blasted surfaces. The relationship between the number of black and white pixels and surface roughness is presented. FFT image processing and analyses results explicitly imply that the technique is useful in the determination of surface roughness.

### Acknowledgments

The measurement and evaluation processes of this study were carried out at Yıldız Technical University and Vienna University of Technology, Interchangeable Manufacturing and Industrial Metrology, Nanotechnology Laboratory.

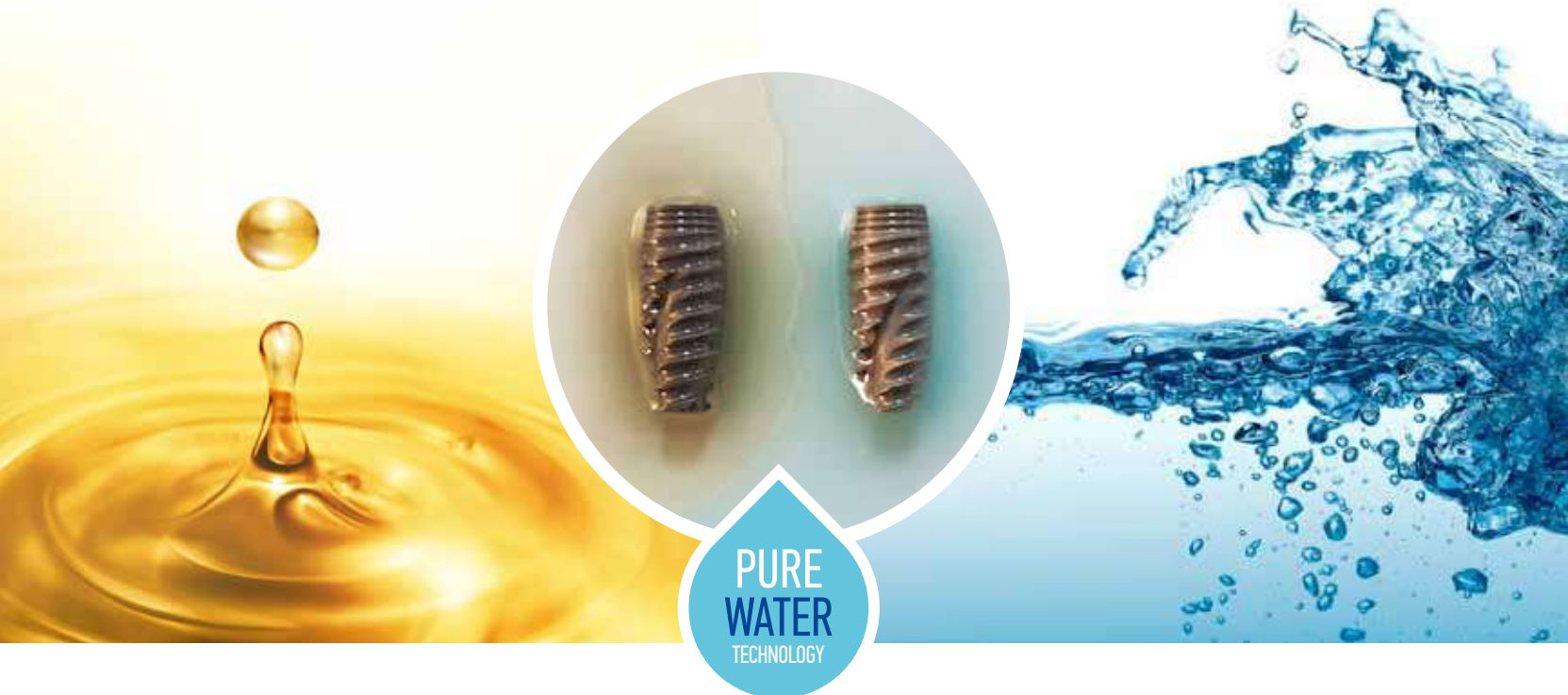The titanium dental implant samples were provided from Mode Medical Company.

<https://aip.scitation.org/doi/pdf/10.1063/1.4914215?class=pdf>

# OUR EXPERIENCE CREATES OUR DIFFERENCE

In the traditional method, **INDUSTRIAL CHEMICAL OILS** need to be used in CNC machines.

MODE MEDIKAL use **PURE WATER TECHNOLOGY** in its manufacturing process, which was developed by the R&D engineers.



## INDUSTRIAL CUTTING OILS

## PURE WATER TECHNOLOGY

Anaerobic Bacteria Formation  
Resin Layer Formation on Implant Surfaces  
Surface Acid Cleaning Process  
Passivation of acid concentration

Hygienic Production  
Pure Water Ultrasonic Cleaning  
No Acid  
No Acid Passivation



## Homogeneous Surface Roughness

%100 Homogen Micro surface Roughness  
Control Process RA ROUGHNESS AVERAGE  
1,4~1,8micron

- Purity, superior cleanliness and biocompatibility
- Enhanced implant anchorage,
- Increased cell development,
- Consistent surface finish thanks to a fully controlled treatment process,
- Achievement of successful osseointegration in more than 98,2% of the cases.





## Experimental Evaluation Of Osseointegration Levels Of Grade 4 Titanium Alloys Used In Dental Implantology With Different Surface Properties


In our study, our aim was to observe osseointegration performance of dental implants with different surface characteristics. Three different implant surfaces were manufactured which have similar macro characteristics but different surface properties: implants with TiO<sub>2</sub> sandblasted surfaces, implants with BCP sandblasted surfaces, recently produced implants with BCP sandblasted and H<sub>2</sub>O<sub>2</sub> dispensed surfaces. Also control group was used with polished surfaces as a fourth specimen group.

Surface characteristics of specimen groups were investigated by 3D and 2D methods. Average Ra surface roughness values of all surfaces were measured with contact stylus profilometer device. To achieve more accurate surface images, surface topographies were also investigated with scanning electron microscope (SEM).

3D morphological investigations were applied with three dimensional modelling by means of optic microscope (Keyence 3D laser) in Vienna Technical University, Nano Technology Laboratory. Both the homogeneity of surface morphology achieved with surface modifications and the roughness values of surfaces were evaluated by these methods.

For in vivo test, dental implants with different surface properties were randomly placed in right and left femoral epiphyses of 28 New Zealand rabbits. In postoperative 3rd and 6th weeks rabbits were sacrificed and osseointegration levels in different time intervals were evaluated using Resonance Frequency Analysis and Removal Torque Test methods. In this experimental study, BCP sandblasted and H<sub>2</sub>O<sub>2</sub> dispensed surface implants were found to be more successful than TiO<sub>2</sub> sandblasted surface implants and TiO<sub>2</sub> sandblasted surface implants were found to be more successful than control group implants in all experimental analysis.

In 6th postoperative week, BCP sandblasted surface and BCP sandblasted and H<sub>2</sub>O<sub>2</sub> dispensed surface implants reached desired 1SQ and RTV values. Therefore its suggested that dental implants with such surface properties may be prosthetically loaded after six weeks.




Totally 56 implants with 3 different surfaces were provided by Mode Medikal

<https://tez.yok.gov.tr/>

Thesis No : 384423

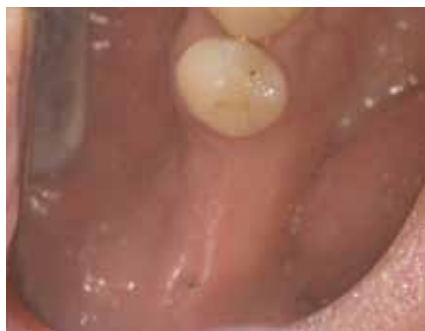2014



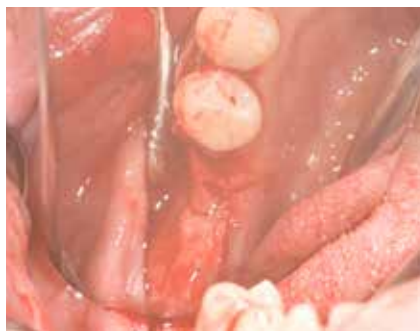**Dr. Uğur Meriç**

ORAL MAXILLOFACIAL SURGERY DDS, PHD

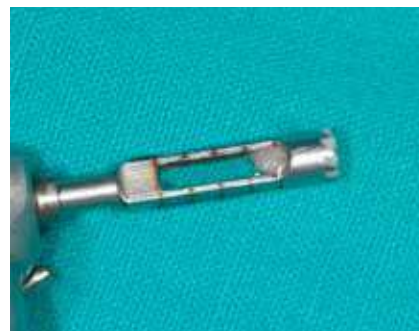# GREFTLESS IMPLANTOLOGY



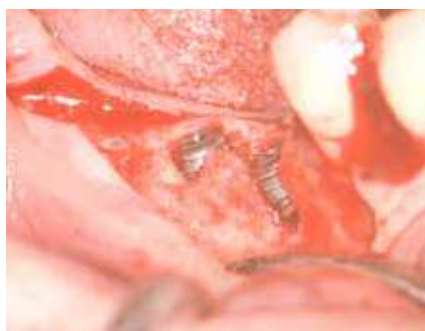**Pic 1**  
Thin crestal bone



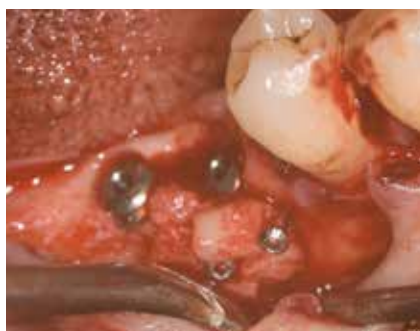**Pic 2**  
Bone after incision



**Pic 3**  
Bone carrot collected with a trephine burr

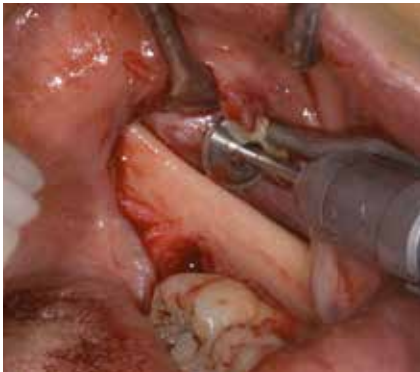

**Pic 4**  
Dehiscence after implant placement

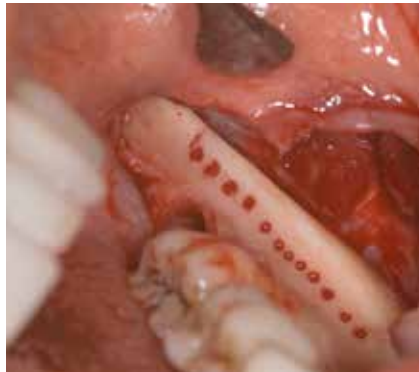

**Pic 5**  
Closing the dehiscence with bone carrot and particulated bone. Stabilisation is achieved with two microscrews.

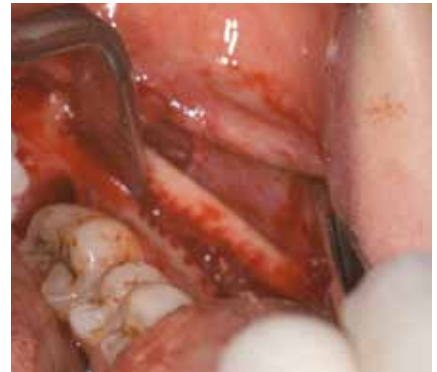Small dehiscences around implants can be augmented with bone carrots and particulated bone. In this case microscrews are used to stabilise the bone carrot.



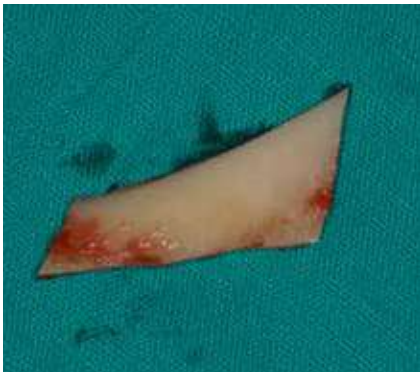**Pic 1**  
Horizontal cut during block removal.



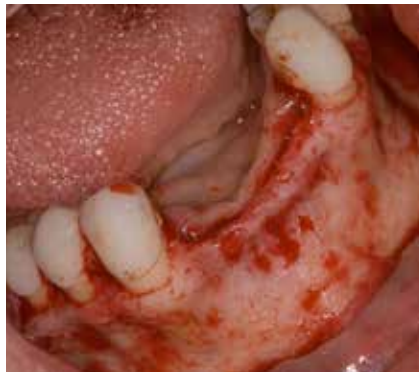**Pic 2**  
Oclusal perforations



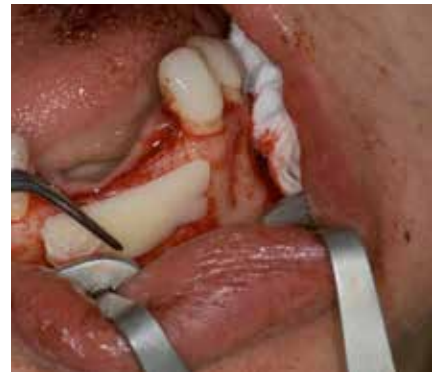**Pic 3**  
Removal of autogenous block



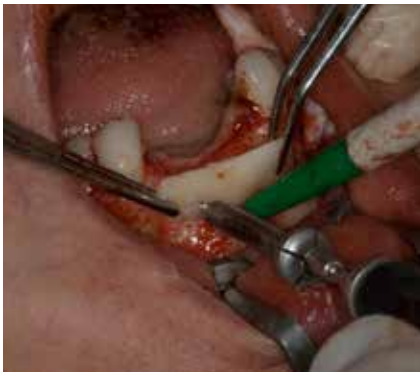**Pic 4**  
Autogenous block



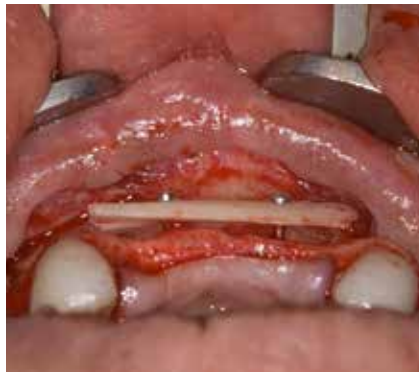**Pic 5**  
Very thin crest



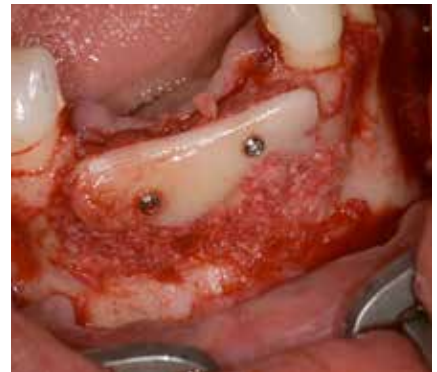**Pic 6**  
Re-shaping block to defect area



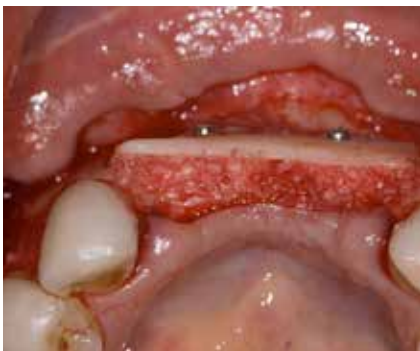**Pic 7**  
Stabilising the block with micro screws



**Pic 8**  
Distance between block and bone




**Pic 9**  
Vestibular view



**Pic 10**  
Filling the distance in between with particulated bone

Biological way of bone augmentation is the most predictable way of bone reconstruction. In this case a thin bone block was placed to thin block with a distance and then filled with particulated bone.  
(Operation: Dr. Uğur Meriç, Dr. Ülkem Cural)



**Dr. Ahmet Kığılı**  
PROTHODONTICS

# PARADIGM SHIFT IN HYBRID PROSTHESIS

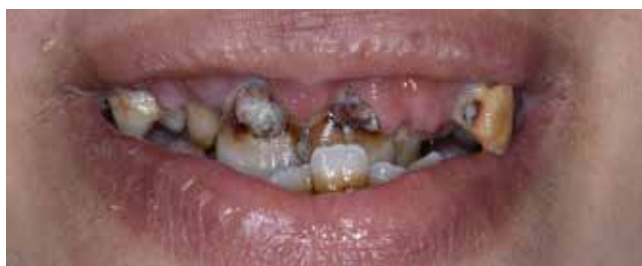

Figure1: During intra oral examination we observed increased vertical dimension and inferior prognathism in extra oral examination.

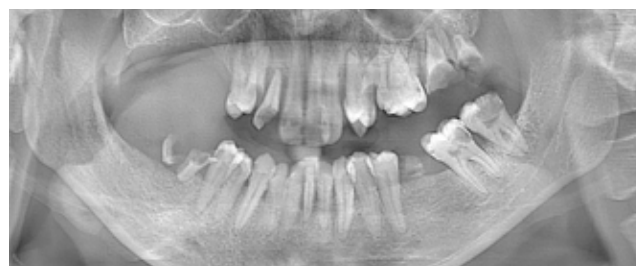

Figure2: X-Ray shows massive attachment loss in both bone and gingiva

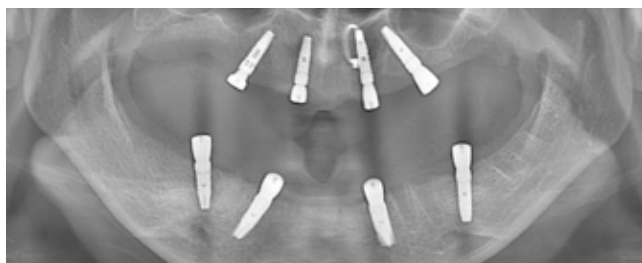

Figure3: 3 months after implantation

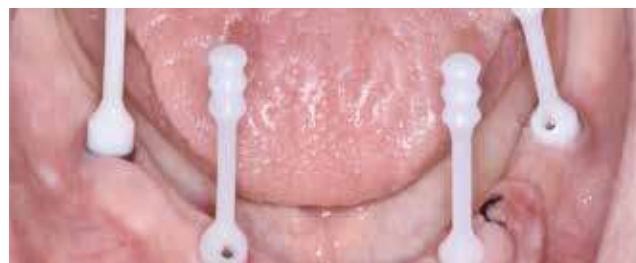

Figure4: Four Multi base abutments placement

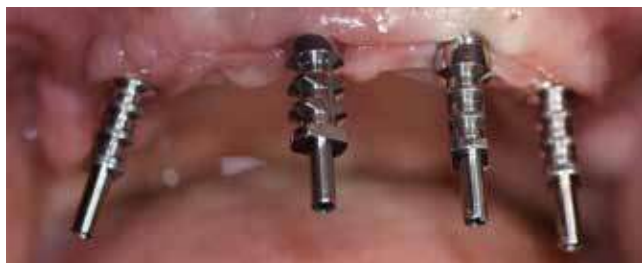

Figure5: All the transfers placed and ready for the impression taking

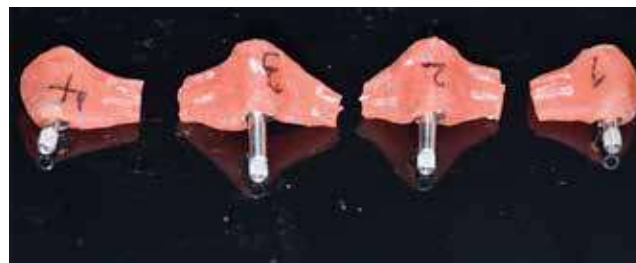

Figure6: put the split impression key in order of their placement turn in the mouth and number them.

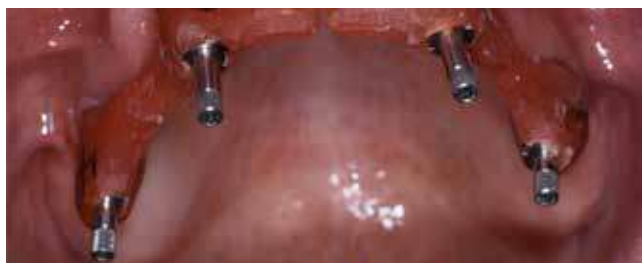

Figure7: We placed this four key parts on the multi base abutment one by one .



Figure8: We are ready for final impression step

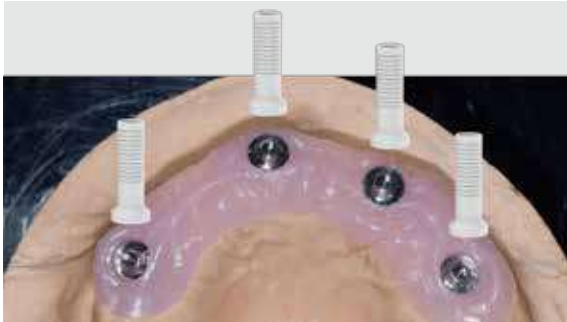

Figure9: Placement of plastic burn out sleeves

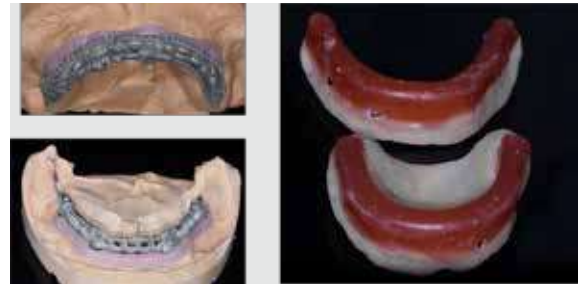

Figure10: Metal framework and wax rims

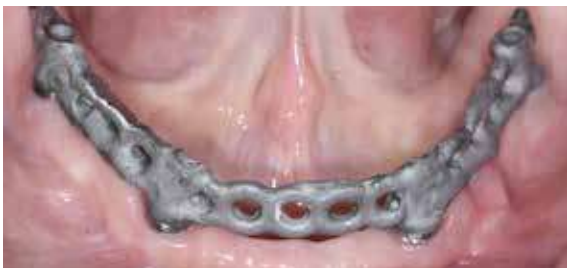

Figure 11: Metal frame work on the multi unit abutments

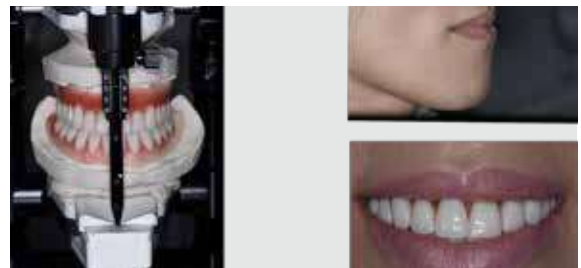


Figure12: Dentures and right smile position..

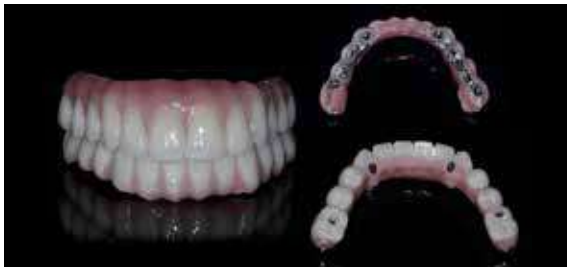

Figure31:An implant-supported hybrid prosthesis is an acrylic resin complete fixed dental prosthesis

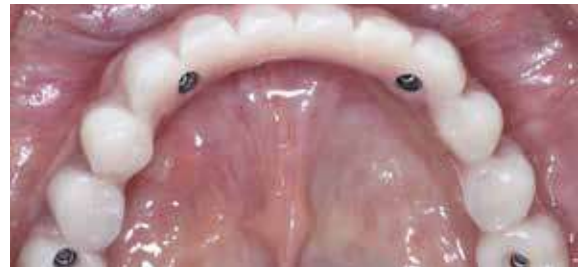

Figure14:Fixed hybrid prosthesis on multi base abutments

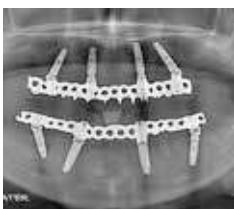

Figure15:No implants failed in This patient after prosthetic rehabilitation during the 3-year follow-up period..

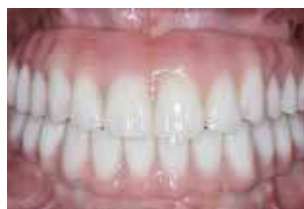

Figure 16: Hybrid Prosthesis mouth view

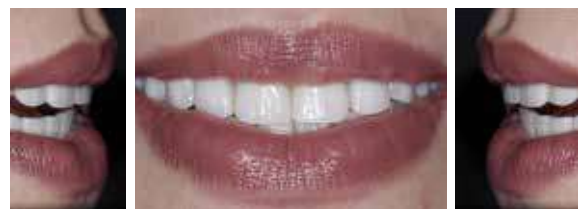

Figure17: Final

36 years old female patient with generalized aggressive periodontitis and dental anomali complaints, came to the clinic. During the primer examination we found pockets of around 7mm depth with flowing purulent matter. on the other hand we measured massive attachment loss in both bone and gingiva ,upper and lower jaw. During intra oral examination we observed increased vertical dimension and inferior prognathism in extra oral examination. The patient was suffering from sever pain, gum bleeding, bad smell and teeth sensitivity; and she had aesthetic rehabilitation demands at the same time. All remained teeth removed and after 3 months of healing period , 8 implants placed in upper and lower jaws.(dimensions 3.7 and 4.1 mm) during the osseointegration period we preferred to benefit an temporary denture with teeth to teeth occlusion which could fulfill the patients normal oral functions. Hybrid prosthesis have a great number of advantages including reducing the impact force of dynamic occlusal loads, being less expensive to fabricate and highly esthetic restorations.. We can have good support for lips and soft tissues. However, we will see food impaction, a bit speech problems with hygiene problems.. if your patients use this hybrid prosthesis they should have oral self care behavior.

# 98% SUCCESS OF MODE IMPLANT SYSTEM

Since 2012 I am using Mode Medical Products in my clinic. I applied up to 1500 Mode Implants my patients. I am trying to file and follow my cases meticulously. I am very satisfied with the results of 5 years follow-up cases with up to %98 success rate.

**CASE 1**  
**AGE:54**  
**SEX:MALE**  
**Systemic disease: non**

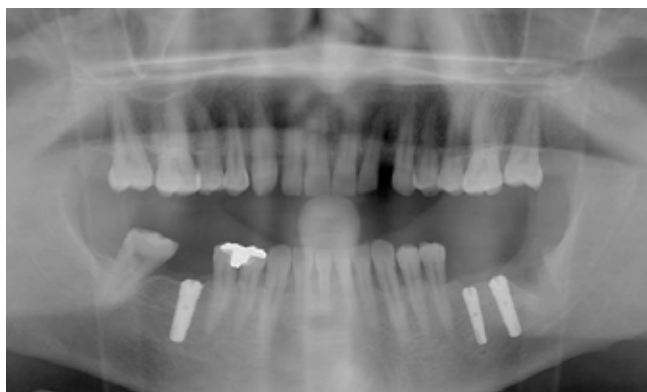

FIGURE 1: Post-op

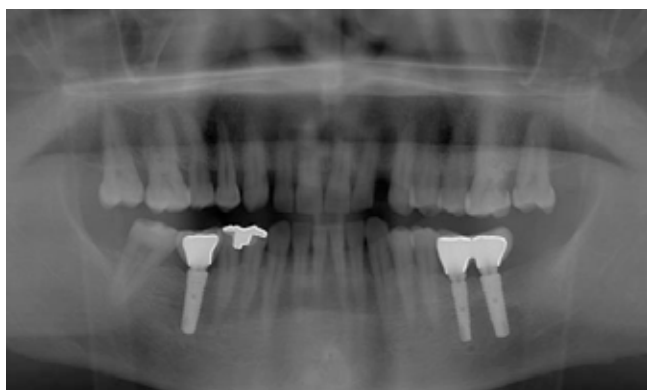


FIGURE 2: 5th year control

**CASE 2**  
**AGE:59 SEX:MALE Systemic disease: Diabetes**

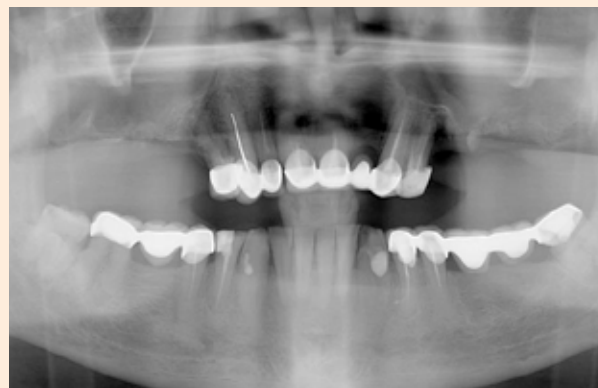

FIGURE 1:  
Pre-op

**CASE 3**  
**AGE:47**  
**SEX:MALE**  
**Systemic disease: non**

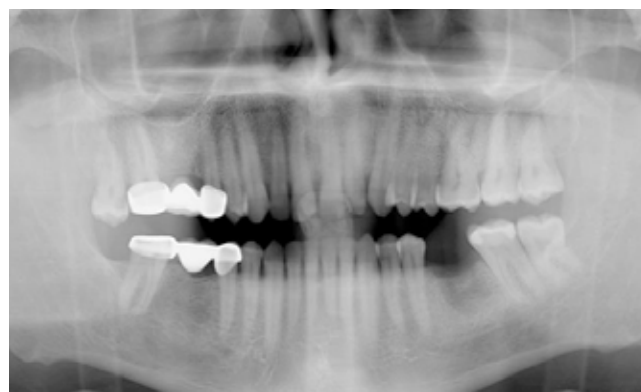

FIGURE 1: Pre-op

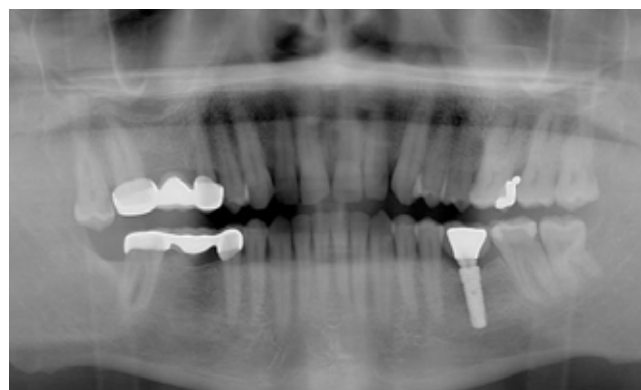
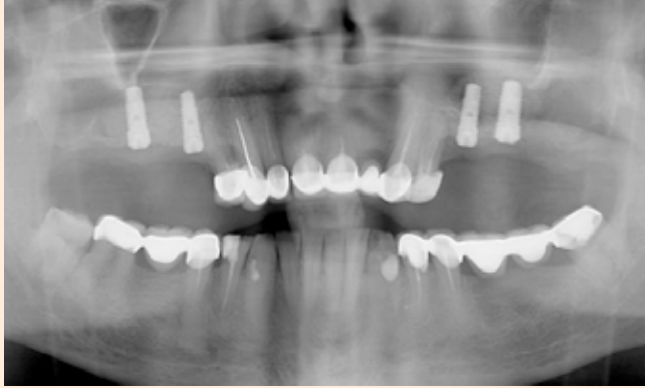
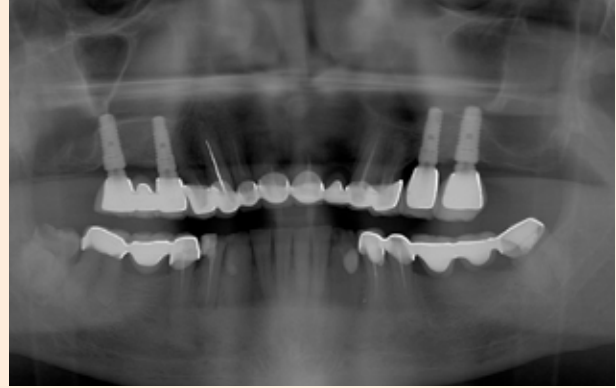FIGURE 2: 5th year control

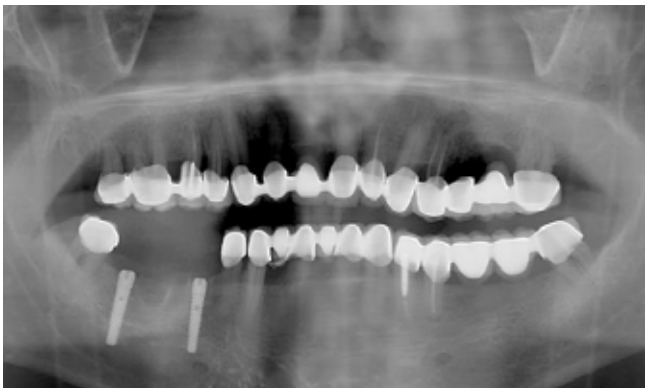

**FIGURE 1:**  
Post-op

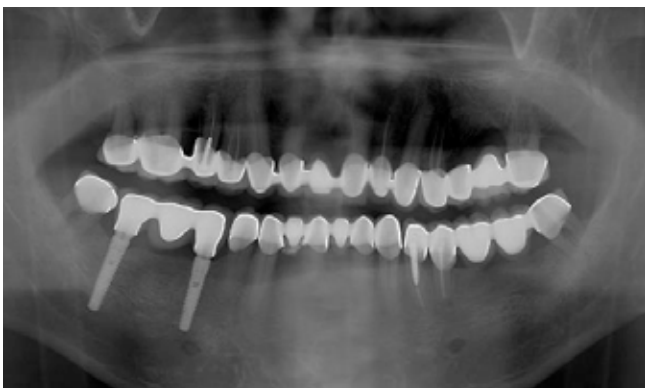

**FIGURE 2:**  
5th year control

**CASE 4**  
**AGE:75**  
**SEX:MALE**  
**Systemic disease: Hypertension**



**FIGURE 1:** Post-op




**FIGURE 2:** 5th year control



## Dr. A. Selhan Kaya

**ORAL AND MAXIOFACIAL SURGEON**

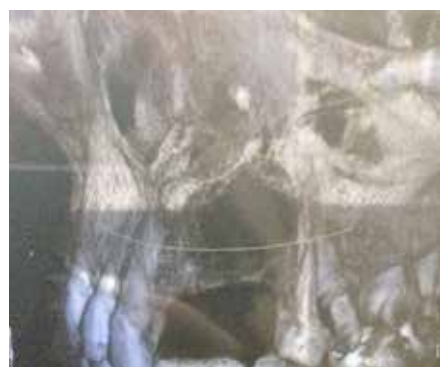He graduated from Istanbul University Faculty of Dentistry in 2005. At the same year, he started his doctorate education in the field of oral and maxillofacial surgery in Istanbul University. Between 2005-2010 he carried on his academic and clinical studies in Istanbul University Faculty of Dentistry. He successfully completed his thesis study on surface characteristics of dental implants and he is entitled as Oral and Maxillofacial Surgeon. He is a member of various charities and professional associations. He is a board member of Turkish Dental Chamber of Antalya since 2012 and also General Secretary of 16th term. He is also a delegate of Turkish Dental Association. He continues his studies in Asklinik Oral and Dental Health Clinic in Antalya since April 2011.



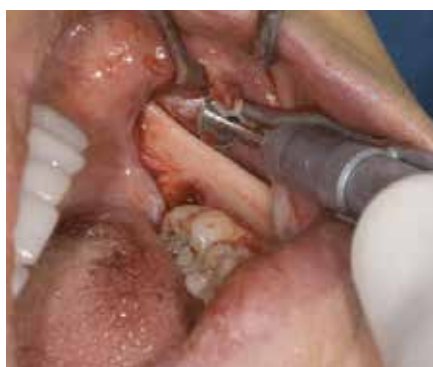## **Dr. Ülkem Cural**

**ORAL MAXILLOFACIAL SURGERY DDS, PHD**

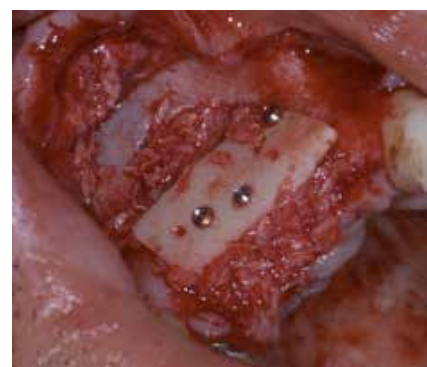22 years old male patient referred to our clinic with fossa canine abscess. After clinic and radiographic examination cystic lesion detected at the right incisor area. Cyst enucleated immediately but unfortunately the related teeth had to be extracted. The pathologic investigation resulted as radicular cyst. After healing prosthetic rehabilitation discussed. The decision was Implant supported fixed prosthesis. but the residual bone was insufficient. The vestibular bone Wall was vanished and there was a dehiscence defect at the palatal Wall. 3D bone augmentation with mandibular ramus bone block graft was planned. 4 months after fist surgery implants were placed. Waited for 3 months for osteointegration and final prosthesis applied.



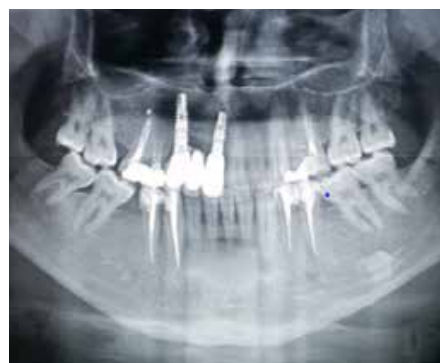**Photo 1:** Bone defect after cyst enucleation



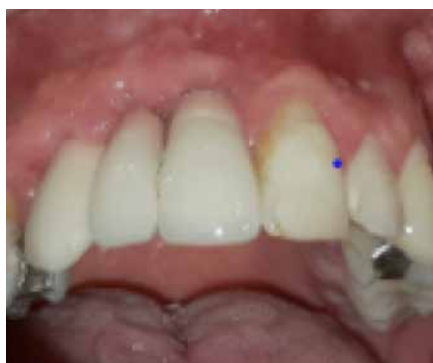**Photo 2:** Harvesting bone block from ramus of mandibula



**Photo 3:** Augmented defect area



**Photo 4:** Radiography of implants with prosthetic rehabilitation



**Photo 5:** Final intra oral view



## Dr. Uğur Mercan

ORAL AND MAXILOFACIAL SURGEON

60 years old male patient was referred to our oral and maxillofacial surgery department about complaining of dental infection in the left posterior region of the maxilla. He was a diabetic patient and his HbA1c level was 11.2 (mmol/mol). Patient was consulted to endocrinology department after the endocrinology treatment HbA1c level were increased and infected teeth were extracted under the prophylaxis antibiotics protocol. After 3 months the patient's HbA1c level was decreased to the 7.1 (mmol/mol) and the implant treatment was decided. We planned to place implant with sinus lift at the same surgery. A-PRF and I-PRF were applied to sinuslift according to the Choukroun protocol. 2 MODE implants (3.7x11.5, 4.7x8mm) were placed to the maxillar left molar area. 6 month later implant crown was placed by prosthodontist. After 2 years followed up, a periapical radiograph was taken to check bone level of implant. According to the clinical and radiographic examination results, there was no bone resorption around MODE dental implants

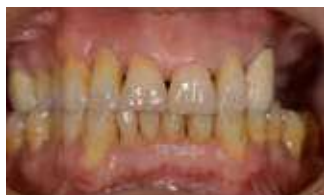

Figure 1. intraoral view of pre surgery

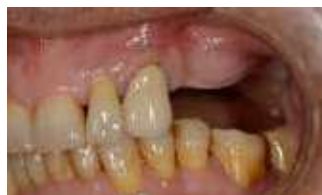

Figure 2. Lateral view of teeth absence in posterior maxilla.

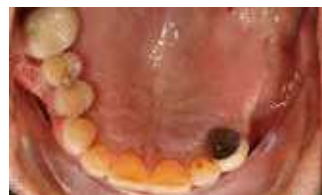

Figure 3. Intraoral occlusal view.

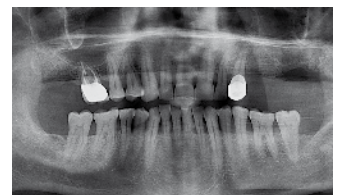


Figure 4. Panoramic view of pre surgery

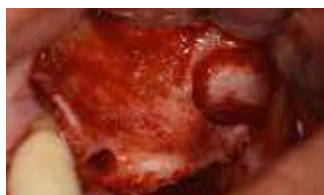

Figure 5. Opened bone window for sinus lift.

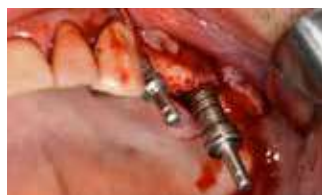

Figure 6. Preparation of implant site.

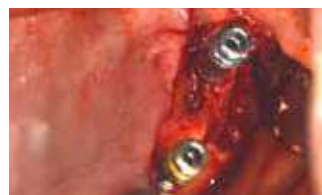

Figure 7. Placed 2 Mode dental implants.



Figure 8. I-PRF was applied to the bone graft

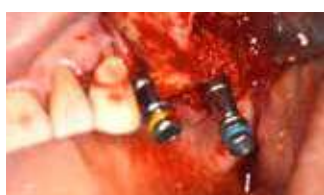

Figure 9. Placed Mode dental implants.



Figure 10. A-PRF and I-PRF were applied to sinuslift area.

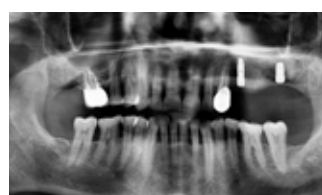

Figure 11. Panoramic view of post surgery.

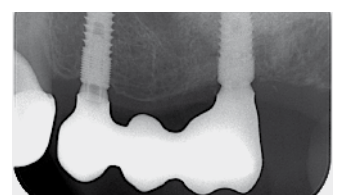


Figure 12. Periapical radiograph view of 2 years followed up.

# IMPLANT PLACEMENT AND SIMULTANEOUS GUIDED BONE REGENERATION IN CONGENITALLY MISSING PREMOLAR: CASE REPORT

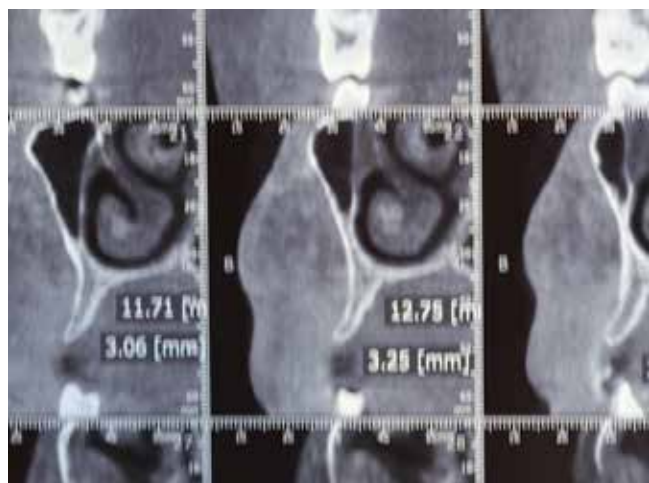
## 5 Years Followup

### Case History:

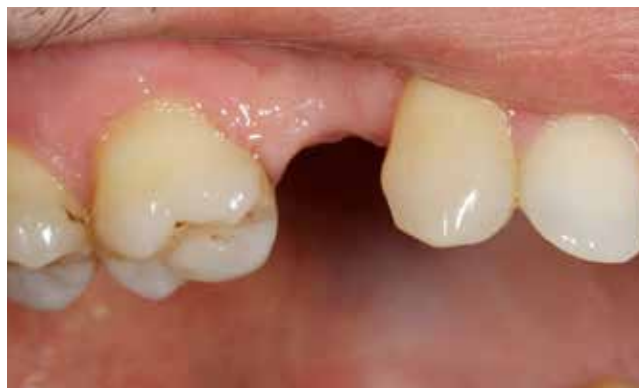42 years old male patient, who has got no systemic diseases and smokes 5-10 cigarettes a day, referred to our clinic for treatment of congenitally missing premolar tooth. In the first phase, initial periodontal therapy was performed. After clinical examination and cbct analyses, implant placement and simultaneous guided bone regeneration therapy with using allogenic bone substitutes and autogenous bone particles, was planned.(Picture 1,2)

Flap elevation was done with midcrestal and vertical incisions (Picture 3,4). In the process of drilling a fenestration defect was formed on vestibular crestal bone as expected. A 3,3mm width and 13mm length implant was placed with 35Ncm insertion torque and a 3mm fenestration defect was formed in vestibular crestal bone (Picture 4). The defect was augmented by a mixture of allogenic bone substitute and autogenous bone. Also collagenous membrane was used for barrier and fixed with membrane pins (Picture 5). Flap closed primarily with single sutures (Picture 6). No early surgical complication was occurred and 10 days later sutures were removed.

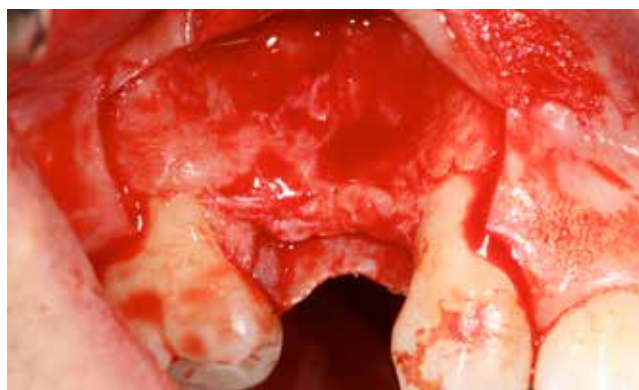We waited for 3 months for osseointegration period. After uneventful osseointegration period gingival former was placed (Picture 7). A cemented, metal supported porcelain crown was delivered (Picture 8). In control radiograph no incidence of bone resorption was seen (Picture 9).



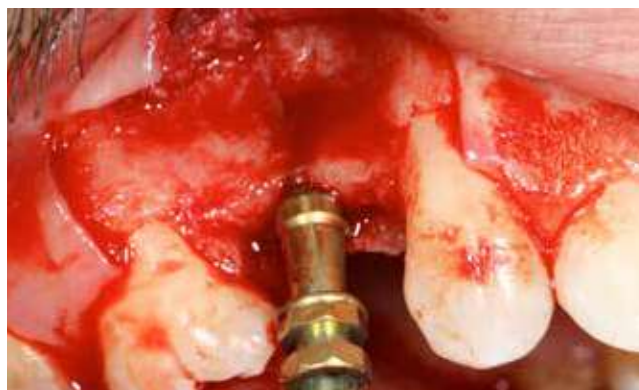Picture 1



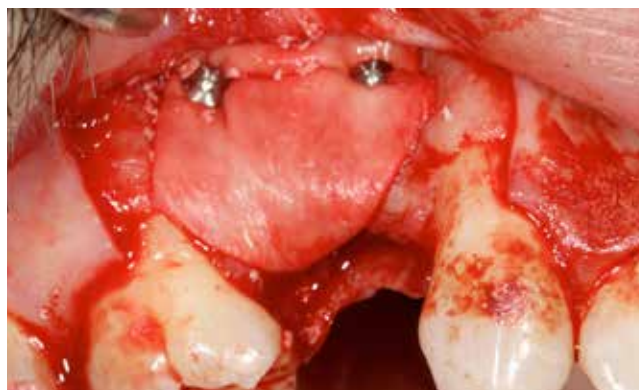
Picture 2



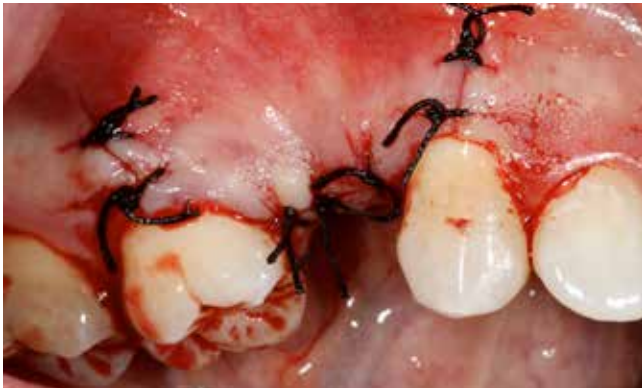Picture 3



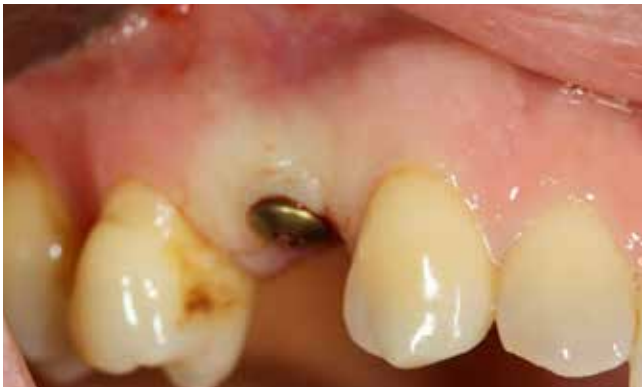Picture 4



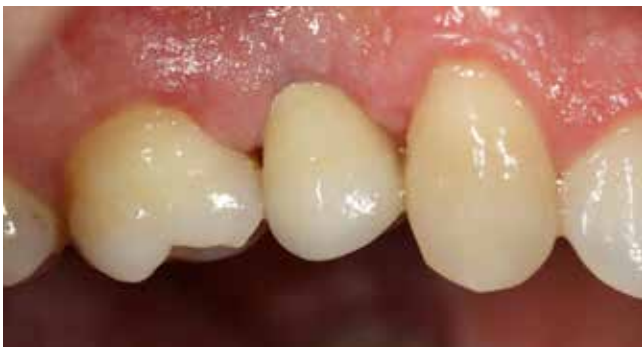Picture 5



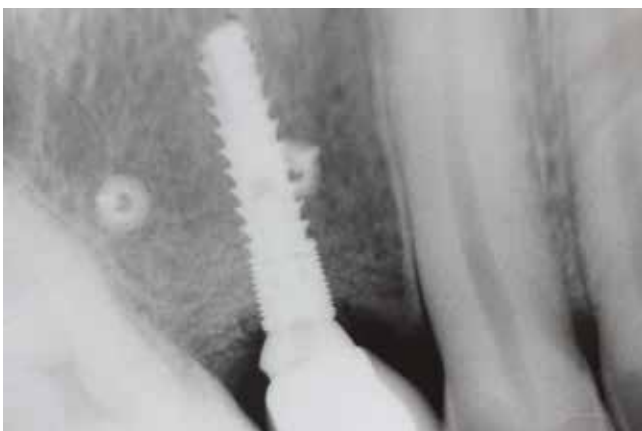
Picture 6



Picture 7



Picture 8



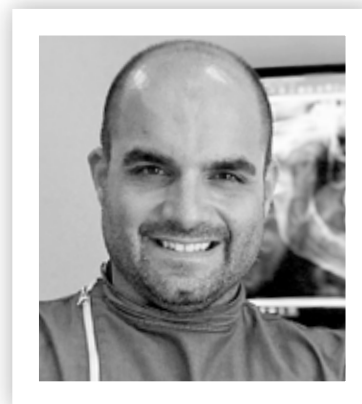
Picture 9

**Discussion:**

Guided bone regeneration is a well-established technique used for augmentation of deficient alveolar ridges with using membranes or not (1).4 major biologic principles necessary for predictable bone regeneration: primary wound closure to ensure undisturbed and uninterrupted wound healing, angiogenesis to provide necessary blood supply and undifferentiated mesenchymal cells, space maintenance/ creation to facilitate adequate space for bone ingrowth, and stability of wound and implant to induce blood clot formation and uneventful healing events (2). In this case we tried to maintain 4 basic principle.

3 mechanism play role in bone regeneration: osseogenesis, osseinduction, osseococonduction. Many different graft materials may induce these mechanism in different proportions. While Autogenous bone has both osseogenesis, osseinduction, osseococonduction characteristics, allografts has osseinduction, osseococonduction and alloplasts has only osseococonduction characteristic. In this case, we used three of characteristics of autogenous bone, and osseococonduction characteristics of allograft material.

Barrier membrane was used for proper guided bone regeneration. sseogenesis, osseinduction, osseococonduction. Collagenous membrane was used for this purpose. Using barrier membranes in bony defects around implants is well documented procedure and collagenous membranes were reviewed as more user-friendly materials than non-resorbable membranes.Also it was concluded that fixation of membrane may represent more predictable healing (3).



**Dr. Volkan Arici**

**ORAL IMPLANTOLOGIST**

**References**

1-Dahlin C, Linde A, Gottlow J , et al. Healing of bone defects by guided tissue regeneration. Plastic Reconstruct Surg. 1988;81: 672-6.  
 2-Wang HL, Boyapati L. "PASS" principles for predictable bone regeneration. Implant Dent. 2006;15:8-17.  
 3- Owens KW, Yukna RA. Collagen membrane resorption in dogs a comparative study. Implant Dent. 2001;10:49-58.



**Dr. Defne Burduroğlu**

PROSTHODONTICS DDS PhD

# DIGITALLY FACBRICATED SCREW RETAINED CROWN

45 year-old male patient admitted to our clinic for the loss of mandibular left first molar. A clinical and radiographic examination was made and an implant treatment was decided for the edentulous space. A Mode Rapid implant with 4.7mm diameter was placed.

3 months after implant surgery, a digital treatment approach was conducted for the screw retained crown prosthetic treatment (Figure 1,2).

Mode scan post and scan body were placed in the mouth for digital impression (Figure 3). A digital impression was taken by using Sirona Cerec AC Omnicam oral scanner (Figure 4).

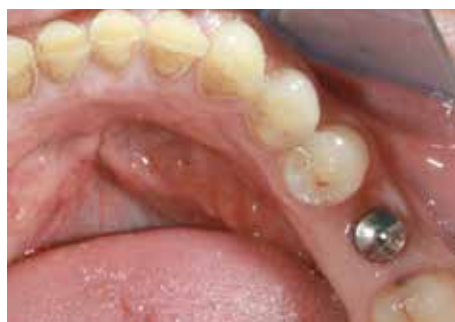

Figure 1

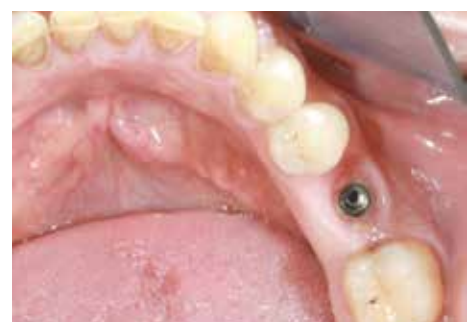

Figure 2

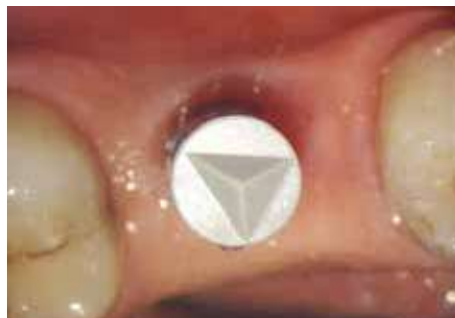

Figure 3

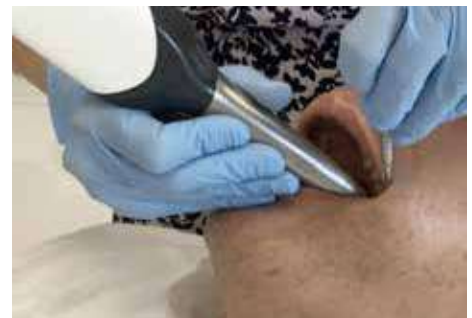

Figure 4

At this stage, the guide lines on the scan post and scan body were checked to be properly aligned (Figure 5).

Following digital impression, the crown was designed using Dentsply-Sirona inLab software (Figure 6,7).

The software automatically transferred screw's path of insertion to the design and made it ready for milling (Figure 8).

The crown was milled from an IPS e.max CAD lithium disilicate block with Sirona CEREC MC XL dental milling machine (Figure 9).

The milled and polished crown was cemented to ti-base abutment with Ivoclar Multilink Hybrid Abutment resin cement in laboratory.

Excess cement was cleaned and cementation area was polished in order to make a smooth finish (Figure 10,11).

The finished one piece crown was placed in mouth and the abutment screw was tightened with 25N/cm2 torque value (Figure 12).

The screw opening was filled with teflon strip and sealed with light-cure composite resin (Figure 13).

Occlusion was checked again during centric and eccentric movements. After necessary adjustments were made, the screw retained crown was delivered to the patient (Figure 14,15).

In recent years, the use of digital methods in dentistry significantly increased globally. With current technology, it is possible to take a digital impression a patient and deliver restorations within the same day by using computer aided design/computer aided manufacturing technology. Digital workflow can be obtained either by taking digital impressions with an oral scanner or by taking conventional impressions and then scanning stone casts. With the help of these techniques, we can both save time and by taking more detailed impressions, we can make more accurately fitting restorations. In this case-report, the production of a screw retained implant supported crown was described.

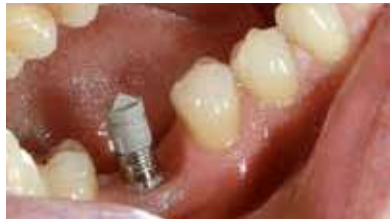

Figure 5

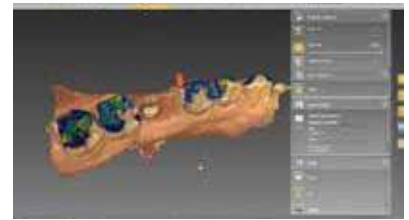


Figure 6

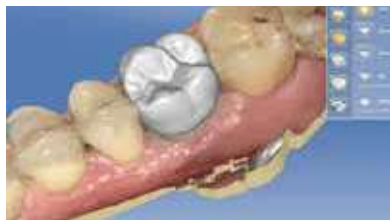

Figure 7



Figure 8



Figure 9

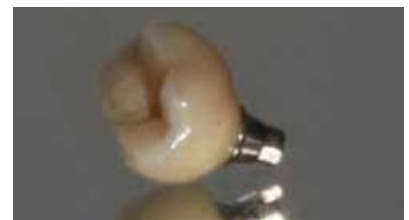

Figure 10

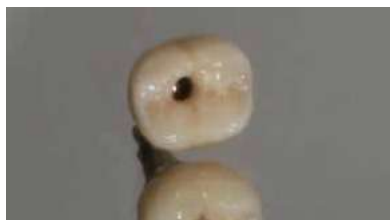

Figure 11

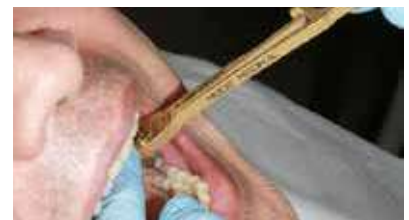

Figure 12

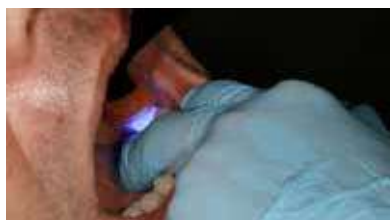

Figure 13

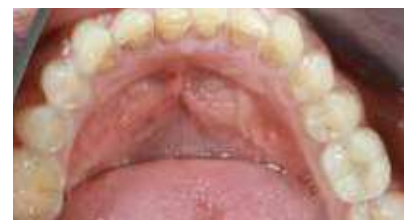

Figure 14

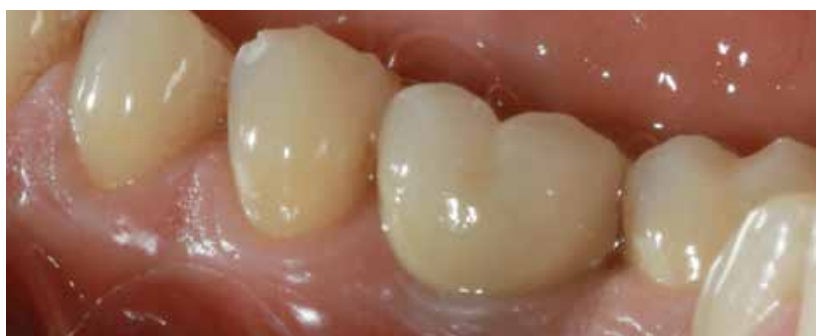

Figure 15



**Assoc. Prof.  
Dr. Yuliya Slynko**

**ORAL MAXILLOFACIAL SURGERY DDS, PhD**

Figure 1 55 years old woman patient, without bad habits and somatic pathology. Turn to clinic with complains about absence of a tooth on right side of mandibula. Tooth was extracted 6 month ago.

Figure 2 During the surgery protocol was collected autogenous bone

Figure 3, 4 Autogenous bone was using in vestibular area after inserting implant. Primary stability of implant was 35Nsm

Figure 5 After 3 month was inserting healing abutment. Conditional of gingiva after 1 month

Figure 6, 7, 8, 9 Final restoration had done by individual CAD CAM system. Individual zirconium abutment, e-max crown. Final resoration was fixed by using cement.

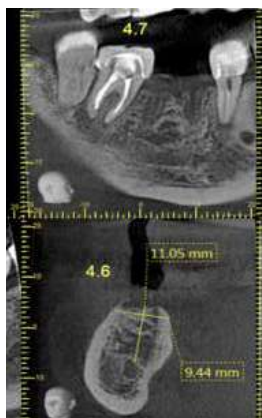


Figure 1

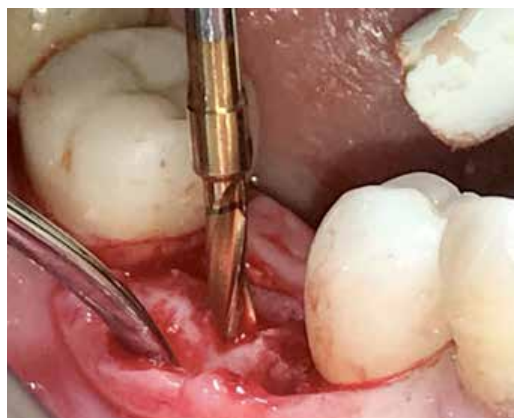

Figure 2



Figure 3

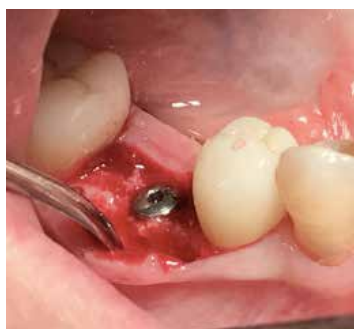

Figure 4

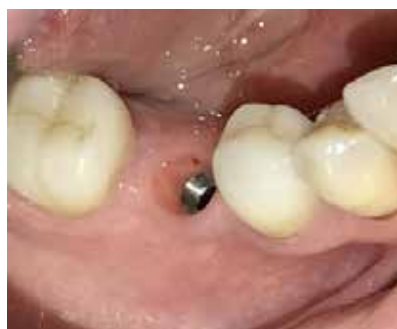

Figure 5

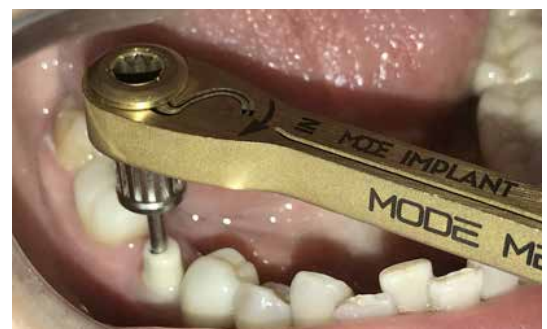

Figure 6

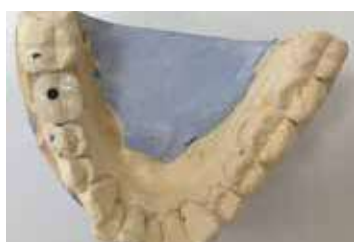

Figure 7

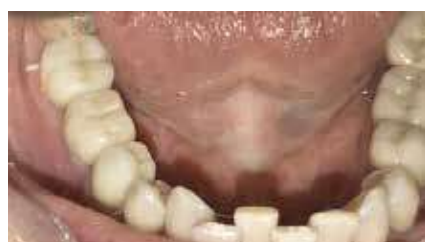

Figure 8

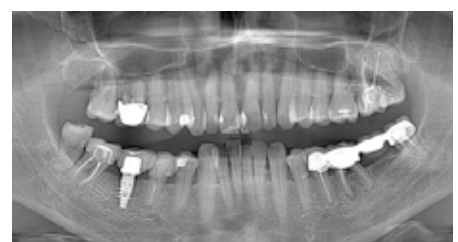

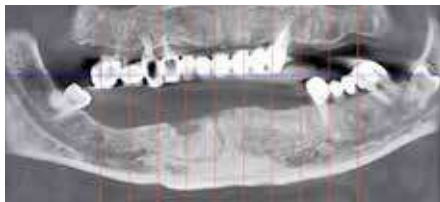Figure 9



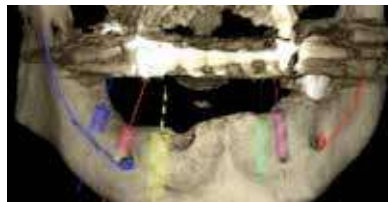# IMMEDIATE IMPLANTATION AND SCREW-RETAINED RESTORATION

**Dr. Fisnik Kasapi**

ORAL MAXILLOFACIAL SURGERY DDS, PhD



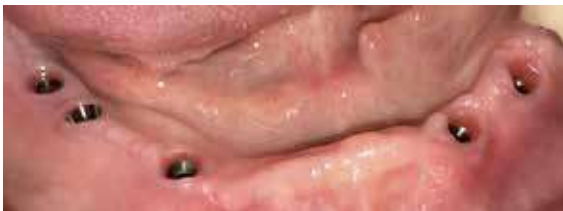**Figure 1** CBCT Panoramic Initial situation before the treatment.



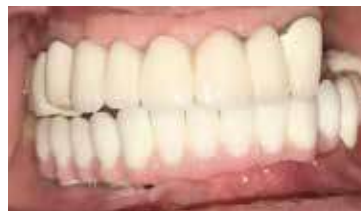**Figure 2** CBCT Planning position of the dental implants



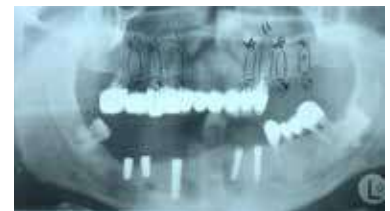**Figure 3** Panoramic x-ray after installation of the implants



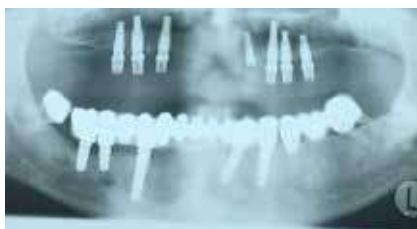**Figure 4** Healthy and clean implant sulcus evident at all of the sites to be restored.



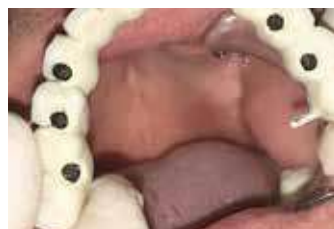**Figure 5** Cemented prosthesis restoration



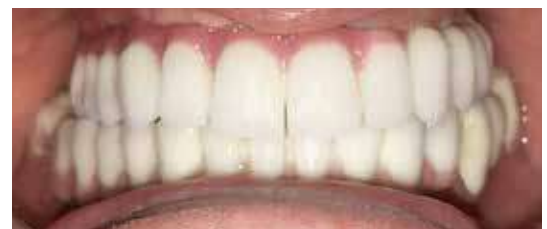**Figure 6** Pre-operative panoramic radiograph for planning purposes in maxilla position 15,14,13,22,23,24,25



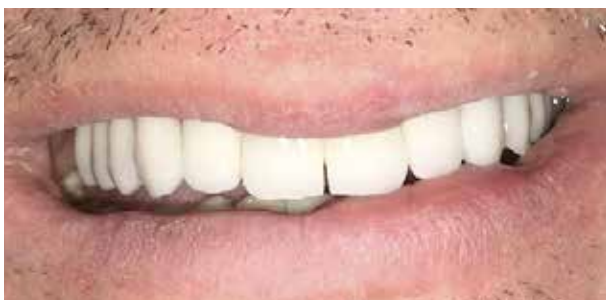**Figure 7** Panoramic x-ray after installation of the implants & abutments in maxilla



**Figure 8** Occlusal view of final restoration



**Figure 9** Facial view of the final screw-retained restoration




**Figure 10** The patient's smile with definitive restorations

**Figure 1** CBCT Panoramic Initial situation before the treatment. **Figure 2** CBCT Planning position of the dental implants **Figure 3** Panoramic x-ray after installation of the implants **Figure 4** Healthy and clean implant sulcus evident at all of the sites to be restored. **Figure 5** Cemented prosthesis restoration **Figure 6** Pre-operative panoramic radiograph for planning purposes in maxilla position 15,14,13,22,23,24,25 **Figure 7** Panoramic x-ray after installation of the implants & abutments in maxilla **Figure 8** Occlusal view of final restoration **Figure 9** Facial view of the final screw-retained restoration **Figure 10** The patient's smile with definitive restorations.

# BIOCOMPATIBILITY (ANIMAL) TEST REPORTS


[www.miacademy.net](http://www.miacademy.net)



**IRRITATION TEST**


Irritation Test was made based to ISO 10993-10, ISO 10993-2 and ISO 19993-12 standards.

The test was performed on 3 New Zealand rabbits and there were no any edema, erythema and irritation observed.




**ACUTE SYSTEMIC TOXICITY TEST**

Acute Systemic Toxicity test report was performed based to ISO 10993-11, ISO 10993-2 and ISO 10993-12 standards. According to the observations of clinic symptoms, gross pathology findings during the test and observations after the test, no acute toxicity was found on the medical materials.




**SUBCHRONIC SYSTEMIC TOXICITY TEST**

Subchronic Toxicity Test Report was performed according to ISO 10993-11, ISO 10993-2 ve ISO 10993-12 standards. According to the Subchronic Toxicity Test Report, it was determined that there is no subchronic systemic toxics effect.




**IMPLANTATION TEST**

Implantation Test was performed according to ISO 10993-11, ISO 10993-2 and ISO 10993-12 standards. Implantation tests target to elucidate local effects of biomaterials after implantation, therefore macroscopic and microscopic histologies are examined with this test.




**SENSITIZATION TEST**

Sensitization Test was performed according to ISO 10993-10 standards. The sensitization test was performed by using adult female guinea pigs. In the test, there was no any weight loss observed on the animals and it was determined that their health circumstances were the same as before.



**CYTOTOXICITY TEST**


Cytotoxicity Test for biological evaluation of medical products was performed by considering ISO 10993-5 in vitro cytotoxicity and no any cytotoxicity effect was observed according to the viability test which was performed by dental implant extraction method.



**BACTERIAL REVERSE MUTATION TEST**

Genotoxicity Test performed according to ISO 10993-3 and ISO 10993-12 standards.

The materials which were tested under the conditions of the test and the mentioned strain of bacteria have no ability of creating mutations.



**BIOBURDEN TEST**

According to the Bioburden Test Report, there is no microorganisms were found on Mode Implant products before sterilization.



**DYNAMIC FATIGUE TEST**

Dental Implants was performed in the laboratory of Ataturk University, according to ISO 14801 standards.

Mode Implant, Ø3.3 mm implants were not deformed at 180 N load.



**TORSION TEST**

Torsion Test of Implant/Body Connecting Part Joints of Endosseous Dental Implant System was tested by Ataturk University according to 13498.

Ø3.3 mm implants did not change their shapes up to 77 Ncm load.



**AGING TEST**

The test objective is determination of shelf life by using accelerated aging method ASTM F 1980.

Dental implant was aged according to the 5 Years aging time. As a result, not detected physical deformation at the samples and keep its sterility.



**CHEMICAL ANALYSIS REPORT**

The report shows that Titanium raw material does not include any incompatible alloying element.



**LEAKING TEST**

Leaking Test was made according to ASTM F 1929 standard.

After 5 years shelf life period, Mode Implant was tested and any leaking was seen in the package.




**OIL GREASE TEST**

Mode Implants products were tested according to ASTM F 2549-12. Because of Pure Water Technology, there was no oil grease seen on implant.



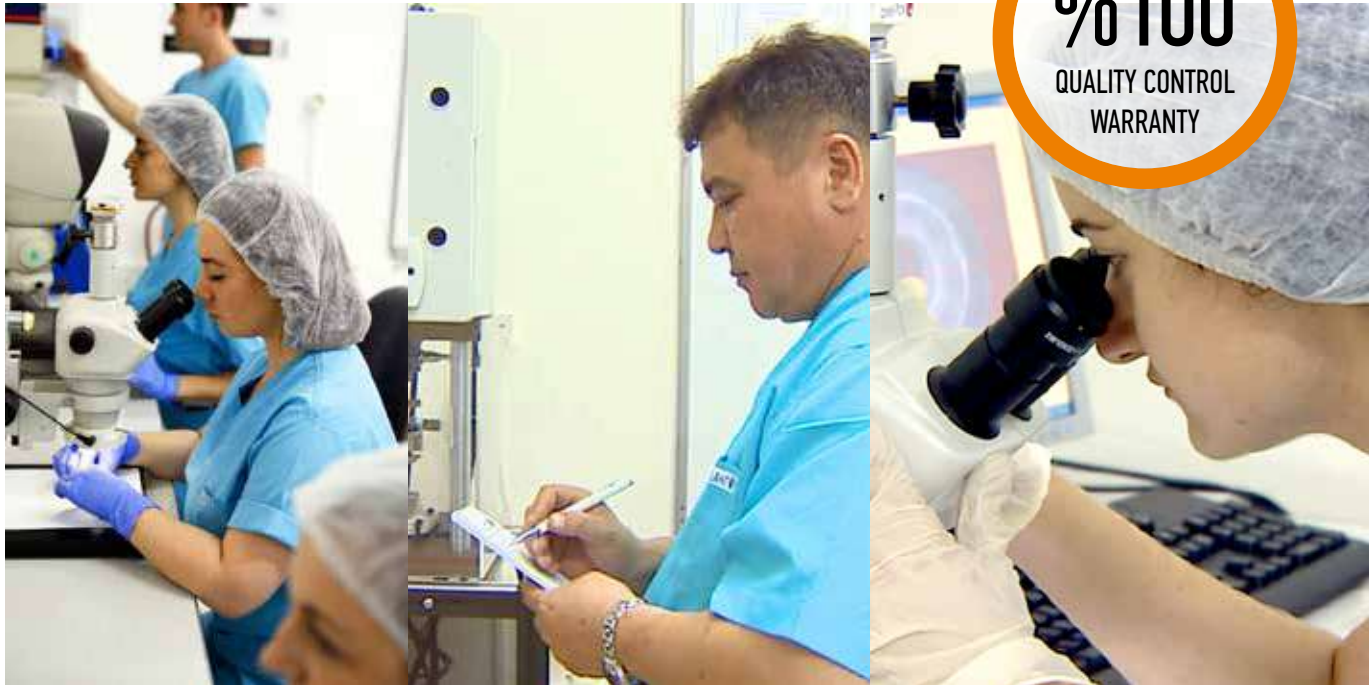**BIOCONTAMINATION TEST**

Cleanroom and associated controlled environments was tested according to ISO 14698. The rate of viable particles settle on the surface, air, hand, textile and surface biocontamination of cleanroom was tested and conformability of it reported.



**STERILITY TEST**

Sterility Test was made according to the norms of ISO-11737-2 and dental implants were tested after their gamma sterilization. It has been documented that the products are sterilized 100% by controlling the effectiveness of irradiation performed.



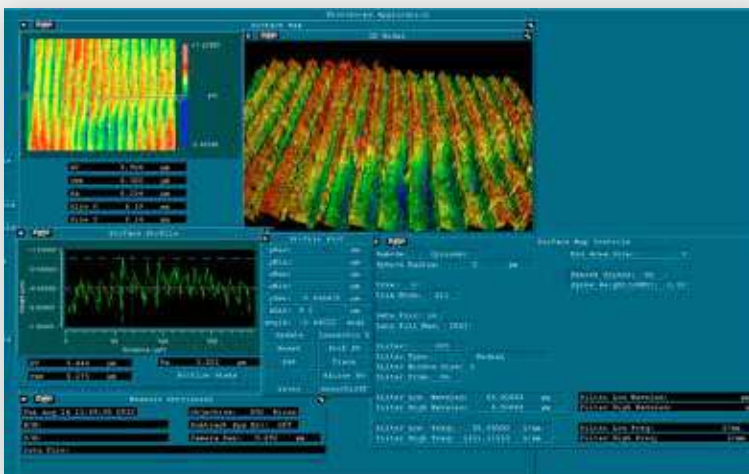
**RADIOGRAPHIC INSPECTION TEST**

Radiographic Inspection Test Report is made by X-Ray device. There were no micro cracks and internal discontinuities observed according to the test report which was made on implants in different diameters and lengths .



**MTS CELL PROLIFERATION ASSAY**

Stem cell culture was performed for 3 days on the implants. In MTS Cell Proliferation Assay, sand blasted surface of implants had 23.3% more cell proliferation.



**SURFACE ROUGHNESS TEST**

Surface Roughness Test Report was performed by using 3D optical surface profiling in Metallurgical and Materials Laboratory of Istanbul Technical University.

According to report, it was proved that surface topography of the dental implants after roughening had optimum Ra measurement values and surface of the implants roughened homogeneously.



## 23<sup>rd</sup> UAE INTERNATIONAL DENTAL CONFERENCE & ARAB DENTAL EXHIBITION AEEDC DUBAI 2019



5-6-7 FEB. 2019

### 5 FEB. 2019, TUESDAY

- 11.00 Implant Inserted, what's the next?
- 11.30 HANDS-ON
- 13.30 Collecting and using Autogenous Bone in Implant Surgery;  
Drilling without Saline
- 14.00 HANDS-ON
- 15.00 Case Study Session
- 16.30 Graftless Sinus Lifting
- 17.00 HANDS-ON

### 6 FEB. 2019, WEDNESDAY

- 11.00 Collecting and using Autogenous Bone in Implant Surgery;  
Drilling without Saline
- 11.30 HANDS-ON
- 13.30 Implant Inserted, what's the next?
- 14.00 HANDS-ON
- 15.00 Case Study Session
- 16.30 Graftless Sinus Lifting
- 17.00 HANDS-ON

### 7 FEB. 2019, THURSDAY

- 11.00 Graftless Sinus Lifting
- 11.30 HANDS-ON
- 13.30 Collecting and using Autogenous Bone in Implant Surgery;  
Drilling without Saline
- 14.00 HANDS-ON
- 15.00 Case Study Session
- 16.30 Implant Inserted, what's the next?
- 17.00 HANDS-ON



**DR. UĞUR MERİÇ**  
ORAL MAXILLOFACIAL SURGERY DDS, PHD

#### Graftless Sinus Lifting

Sinus Lifting is a routine non-invasive oral surgery method. That has been used all over the World. This method has potential downside like sinus infections and low quality of bone created for the implant. Bone substitute of material is a reason for the unexpected complications. Sinus Lifting with bone substitute material will be discussed with case studies, long term success and procedures.



**DR. YULIYA SLYNKO**  
ORAL MAXILLOFACIAL SURGERY DDS, PHD

#### Collecting and using Autogenous Bone in Implant Surgery; Drilling without Saline

Even if the Autogenous Bone is accepted as a "Gold Standard", usage in our daily practices is very limited. Difficulties in acquiring sufficient quantity of the material, needs a secondary surgery and probable resorptions possibilities are the prejudices for the clinicians avoiding autogenous bone in their daily practices. The philosophy indications and application of autogenous bone from simple to complex cases will be discussed in this presentation. Techniques of collecting autogenous bone by drilling without saline.



**DR. HISHAM YOUSEF ABUELJEBAIN**  
M.SC. ORAL SURGEON

#### Implant Inserted, what's the next?

This lecture is intended to present to you the steps to be followed after placing your implants. What would you do in order to come up with the correct prosthesis in the best place.



**DR. UĞUR MERİÇ**  
ORAL MAXILLOFACIAL SURGERY DDS, PHD

### Graftless Sinus Lifting

Sinus Lifting is a routine non-invasive oral surgery method. That has been used all over the World. This method has potential downside like sinus infections and low quality of bone created for the implant. Bone substitute of material is a reason for the unexpected complications. Sinus Lifting with bone substitute material will be discussed with case studies, long term success and procedures.



**DR. YULIYA SLYNKO**  
ORAL MAXILLOFACIAL SURGERY DDS, PHD

### Collecting and using Autogenous Bone in Implant Surgery; Drilling without Saline

Even if the Autogenous Bone is accepted as a "Gold Standard", usage in our daily practices is very limited. Difficulties in acquiring sufficient quantity of the material, needs a secondary surgery and probable resorptions possibilities are the prejudices for the clinicians avoiding autogenous bone in their daily practices.



**DR. FİSİK KASAPI**  
ORAL SURGEON

The placement of a dental implant in the edentulous posterior maxilla often is followed with many difficulties as result of an insufficient bone due to pneumatization of the maxillary sinus and bone resorption after extraction. Few types of autologous materials are available for this procedure. Recently, we have developed new Plasma-Therm protocol for production of new (fully autologous) graft material and barrier membrane. We have evaluated the predictability of the new bone formation at sinus floor after elevation of the membrane using a novel fully autologous Plasma-Therm graft materials (NPTGM) for the first time.

If before has been advised that simultaneous placement is indicated when the height of the residual ridge beneath the sinus floor is at least 5 mm; when it is 4mm or less, the delayed placement technique should be applied, in cases with Mode RAPID Implant system almost 1mm is enough for HIGH INITIAL PRIMARY STABILITY and perfect osseointegration!

WE HAVE THE PLEASURE TO INVITE YOU FOR  
**LECTURES & HANDS-ON**  
IN HALL5 STAND M14  
PARTICIPATION IS FREE



16<sup>th</sup> Istanbul Dental Equipment  
and Materials Exhibition

11-14 April 2019 **CNREXPO**  
YEŞILKÖY-İSTANBUL



Hosting the technology and innovations in the field of global oral and dental health apparatus and equipment, IDEX will be held on April 11-14th 2019.

**FAIR SPACE: 25.000 m<sup>2</sup>**

**ESTIMATED VISITORS: 15.000**

#### EXHIBITORS PROFILE

- Dental Units
- Dental X-ray Machines
- Dental Laser
- Dental Tomography Instruments
- Autoclaves
- Panoramic and Cephalometric Imaging Systems
- Dental Compressors
- Surgical Aspiration Systems
- Ultrasonic Scaler
- Dental Curing Light
- Amalgamators
- Aerator Heads and Micro Motors
- Oral Camera and Digital Radiography Instruments
- Endodontic Products
- Implant Systems
- Periodontal and Surgical Products
- Clinical Consumables
- Laboratory Equipment
- Dental Diagnosis Systems
- Laboratory Consumables
- Sterilization and Disinfection Products
- Aesthetic Dentistry Products
- Disposable Products
- Dental Furniture
- Dental Office Software

# JOIN US IN APRIL 12<sup>th</sup>, 2019

PULLMAN ISTANBUL AIRPORT HOTEL AND CONVENTION CENTER



- Immediate vs. Delayed Socket Management.  
*What we know, what we think we know, and what we don't know...!*
- Multidisciplinary Management of Esthetic Problem Cases.  
*The ultimate test of our knowledge and skills...*



## Dr. Dennis P. Tarnow, DDS

Dr Dennis Tarnow is currently Clinical Professor of Periodontology and Director of Implant Education at Columbia School of Dental Medicine. He is the former Professor and Chairman of the Department of Periodontology and Implant Dentistry at New York University College of Dentistry.

Dr. Tarnow has a certificate in Periodontics and Prosthodontics and is a Diplomat of the American Board of Periodontology. He is a recipient of the Master Clinician Award from the American Academy of Periodontology, Teacher of the Year Award from New York University and Distinguished Lecturer Award from the American College of Prosthodontists in 2015.

Dr. Tarnow has a private practice in New York City, and has been honored with a wing named after him at New York University College of Dentistry. He has published over one hundred seventy five articles on perio-prosthodontics and implant dentistry and has coauthored three textbooks including one titled Aesthetic Restorative Dentistry.

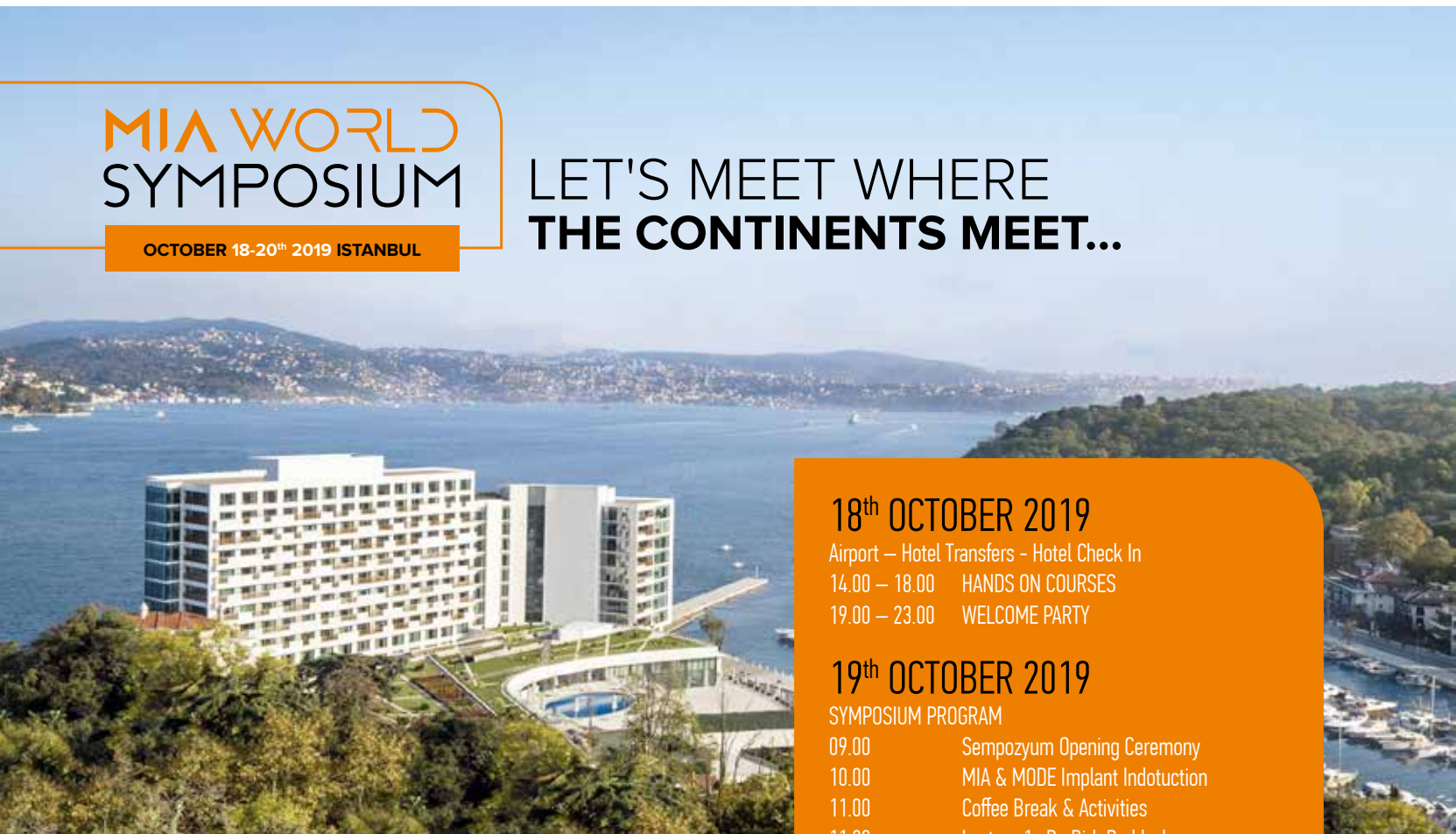Dr. Tarnow has lectured extensively in the United States and internationally in over forty five countries.

|               |  |               |   |
|---------------|--|---------------|---|
| 08:30 - 09:00 | REGISTRATION   | 13:00 - 14:00 | LUNCH   |
| 09:00 - 09:30 | OPENING CEREMONY (AUDITORIUM)  | 14:00 - 15:30 | DR. DENNIS P. TARNOW, DDS<br>Multidisciplinary management of esthetic problem cases.<br><i>"The ultimate test of our knowledge and skills"</i>  |
| 09:30 - 11:00 | DR. DENNIS P. TARNOW, DDS<br>Immediate vs. Delayed Socket Management<br><i>"What we know, what we think we know, and what we don't know..."</i>  |               | <ul style="list-style-type: none"> <li>• Which teeth to save or extract?</li> <li>• Should implants be placed immediately or in a delayed protocol?</li> <li>• Should multiple implants be placed in the aesthetic zone?</li> <li>• When and how to include orthodontics if needed for sight development</li> </ul>   |
|               | <ul style="list-style-type: none"> <li>• Identify what type of healing takes place against the implant in immediate socket placement</li> <li>• How to minimize recession with immediate provisionalization</li> <li>• The proper crown contour for immediate provisionals</li> <li>• If the gap distance really matters?</li> </ul>           | 15:30 - 16:00 | COFFEE BREAK  |
| 11:00 - 11:30 | COFFEE BREAK   | 16:00 - 17:00 | DR. DENNIS P. TARNOW, DDS<br>Multidisciplinary management of esthetic problem cases<br><i>"The ultimate test of our knowledge and skills"</i>   |
| 11:30 - 13:00 | DR. DENNIS P. TARNOW, DDS<br>Immediate vs. Delayed Socket Management<br><i>"What we know, what we think we know, and what we don't know..."</i>  |               | <ul style="list-style-type: none"> <li>• Should pink ceramic be used or should ridge augmentation be performed?</li> <li>• Should the case be splinted or broken up into separate bridges or individual teeth?</li> <li>• How to provisionalize the case throughout treatment</li> <li>• When to immediate load cases versus do a serial extraction case</li> </ul> |
|               | <ul style="list-style-type: none"> <li>• If primary closure should be attempted or should it be left open?</li> <li>• If membranes should be utilized?</li> <li>• What type of graft material if any should be utilized?</li> <li>• What are the potential short and long term risks involved with immediate placement of implants?</li> </ul> | 17:00 - 17:30 | Q & A SESSION   |

# MIA WORLD SYMPOSIUM

OCTOBER 18-20<sup>th</sup> 2019 ISTANBUL

## LET'S MEET WHERE THE CONTINENTS MEET...



### 18<sup>th</sup> OCTOBER 2019

Airport – Hotel Transfers - Hotel Check In

14.00 – 18.00 HANDS ON COURSES

19.00 – 23.00 WELCOME PARTY

### 19<sup>th</sup> OCTOBER 2019

SYMPOSIUM PROGRAM

09.00 Sempozyum Opening Ceremony  
10.00 MIA & MODE Implant Indotuction  
11.00 Coffee Break & Activities  
11.30 Lecture 1 : Dr. Dirk Duddeck  
13.00 Lunch & Activities  
14.30 Lecture 2 : Dr. Frank Zastrow  
16.00 Coffee Break & Activities  
16.30 Lecture 3 : Dr. Ugur Meriç & 3-Musketeers  
18.00 Q&A Session  
19.30 Bosphorus Tour & Gala Dinner  
22.30 Concert

### 20<sup>th</sup> OCTOBER 2019

Hotel Check-Out

Hotel - Airport Transfers



**DR. DIRK DUDDECK**



**DR. FRANK ZASTROW**



**DR. UĞUR MERİÇ**

#### LUNCH & COCTAIL



#### HANDS ON COURSES



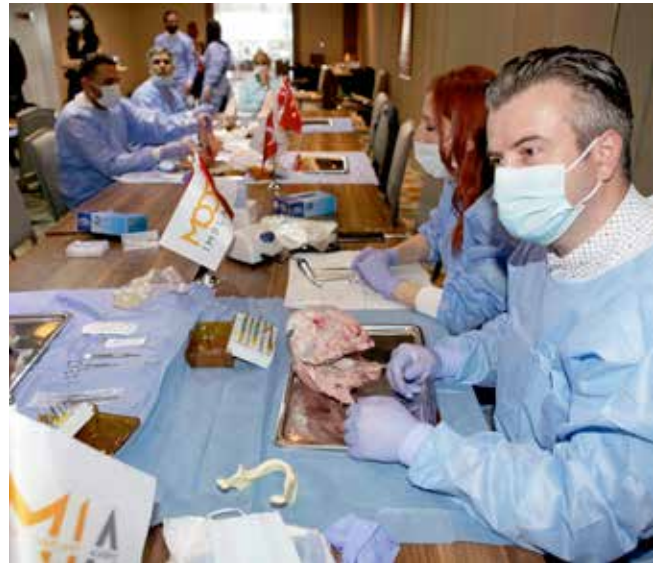#### SYMPOSIUM & CONCERT



## LECTURES & HANDS-ON COURSES

18<sup>TH</sup> OCTOBER 2019 (14.00-18.00)

1. QUATROFIX: ALL ON 4 CONCEPT
2. DIGITAL DENTISTRY: DIGITAL & ANALOGUE MEASUREMENT TECHNIQUES
3. SINUS LIFT TECHNIQUE & IMMEDIATE IMPLANTATION WITH PRF
4. BONE AUGMENTATION SURROUNDING SOFT TISSUE PRACTICES



## SYMPOSIUM LECTURES

19 OCTOBER 2019 (09.00-18.00)

**LECTURE 1.** How clean and safe is your implant?

How can dentists be sure to avoid inferior quality implants? Are there any clinical or legal consequences?

**LECTURE 2.** Biological Bone Augmentation

How to Get Reliable Results Even in Compromised Situations.

**LECTURE 3.** Are You Ready For a Great Discussion?

Different Perspectives of implant dentistry. Implant Surgery and Prosthesis in Systemic indications. Complexity? Synergy?



**BOSPHORUS TOUR & GALA DINNER**



**SOCIAL ACTIVITIES**



**DREAMY CONCERT**

LET'S MEET WHERE  
THE CONTINENTS MEET...

# MIA WORLD SYMPOSIUM

OCTOBER 18-20<sup>th</sup> 2019 ISTANBUL



PROF. DR.  
HASAN MERİÇ



DR. DIRK  
DUDDECK



DR. FRANK  
ZASTROW



DR. UĞUR  
MERİÇ

MODE IMPLANT ACADEMY

+90 212 612 64 09

+90 530 555 88 66

[info@miacademy.net](mailto:info@miacademy.net)

[www.miacademy.net](http://www.miacademy.net)

MODE MEDİKAL®

MODE  
IMPLANT

MIA  
MODE IMPLANT  
ACADEMY